

Henry Ford Health

Henry Ford Health Scholarly Commons

Orthopedics Articles

Orthopedics / Bone and Joint Center

1-1-2017

Chronic thoracolumbar subdural empyema: Case report and surgical management.

Azam Basheer

Henry Ford Health, abashee1@hfhs.org

Mohamed Macki

Henry Ford Health, mmacki2@hfhs.org

Morenikeji Buraimoh

Henry Ford Health

Asim Mahmood

Henry Ford Health, amahmoo2@hfhs.org

Follow this and additional works at: https://scholarlycommons.henryford.com/orthopaedics_articles

Recommended Citation

Basheer A, Macki M, Buraimoh M, and Mahmood A. Chronic thoracolumbar subdural empyema: Case report and surgical management. *Surg Neurol Int* 2017; 8:167

This Article is brought to you for free and open access by the Orthopedics / Bone and Joint Center at Henry Ford Health Scholarly Commons. It has been accepted for inclusion in Orthopedics Articles by an authorized administrator of Henry Ford Health Scholarly Commons.

Case Report

Chronic thoracolumbar subdural empyema: Case report and surgical management

Azam Basheer, Mohamed Macki, Morenikeji Buraimoh¹, Asim MahmoodDepartments of Neurosurgery and ¹Orthopedic Surgery, Henry Ford Hospital, Detroit, Michigan, USAE-mail: *Azam Basheer - Abashee1@hfhs.org; Mohamed Macki - mmacki2@hfhs.org; Morenikeji Buraimoh - mburaim1@hfhs.org;Asim Mahmood - amahmoo2@hfhs.org

*Corresponding author

Received: 05 May 17 Accepted: 29 June 17 Published: 01 August 17

Abstract

Background: Spinal cord abscesses and spinal subdural empyemas are rare and difficult to treat.**Case Description:** A 35-year-old male presented to an outside institution with 2 months of progressive low back pain, weakness, and bowel incontinence; he was diagnosed with an L4 epidural abscess that was poorly managed. When the patient presented to our institution, magnetic resonance imaging (MRI) revealed a well-organized chronic subdural abscess at the thoracolumbar junction. Following resection, his back pain resolved but he was left with a residual paraparesis.**Conclusion:** Subdural abscesses are rare and should be considered among the differential diagnoses for intraspinal mass lesions. Treatment should include prompt surgical exploration and decompression combined with appropriate prolonged antibiotic treatment.**Key Words:** Chronic spinal subdural abscess, epidural abscess, spinal subdural abscess, spinal subdural empyema**Access this article online****Website:**www.surgicalneurologyint.com**DOI:**

10.4103/sni.sni_171_17

Quick Response Code:

INTRODUCTION

Chronic spinal subdural abscesses are rare. They are typically intradural/extramedullary and are only rarely intramedullary in location.^[1,2] Most arise due to hematogenous spread, followed by local extension and iatrogenic contamination. Although they may mimic extradural infections, their intradural location and, therefore, greater severity, may be under-interpreted or misinterpreted, leading to inadequate care. Here, we report a patient who 2 months earlier had undergone an extradural exploration for infection. The failure to accurately locate the intradural phlegmon ultimately resulted in a full-blown cauda equina syndrome, at which point the subdural empyema was appropriately decompressed/evacuated and treated with prolonged intravenous antibiotic therapy.

CASE REPORT

Initial presentation

A 35-year-old male, with a history of intravenous drug and cocaine abuse, presented to an outside hospital with back pain, bilateral lower extremity numbness, and bladder

This is an open access article distributed under the terms of the Creative Commons Attribution-NonCommercial-ShareAlike 3.0 License, which allows others to remix, tweak, and build upon the work non-commercially, as long as the author is credited and the new creations are licensed under the identical terms.

For reprints contact: reprints@medknow.com

How to cite this article: Basheer A, Macki M, Buraimoh M, Mahmood A. Chronic thoracolumbar subdural empyema: Case report and surgical management. *Surg Neurol Int* 2017;8:167.

<http://surgicalneurologyint.com/Chronic-thoracolumbar-subdural-empyema:-Case-report-and-surgical-management/>

incontinence. When magnetic resonance imaging (MRI) revealed a possible epidural collection around the lamina of L4, a lumbar puncture (LP) was performed. The LP revealed numerous polymorphonuclear leukocytes (PMNs); the cerebrospinal fluid gram staining and cultures were negative. The patient underwent an L4 laminectomy, however, no purulence was encountered in the epidural space. Only reactive fibrous tissue and a markedly thickened dura were identified. Despite a negative biopsy and no growth on cultures, the patient was empirically treated with vancomycin for four weeks (e.g., presumptive *Staphylococcal* and *Streptococcal* species).

Second presentation

Two months later, with progressive lower extremity pain, weakness (4/5 mid/distal lower extremities bilaterally), and continued bladder and bowel incontinence, the patient presented to our institution [Table 1].

New magnetic resonance imaging

The new contrast-enhanced high-resolution MRI of the whole neuraxis demonstrated multiple foci of subdural empyema. There were heterogeneous pockets of enhancement along the ventral and dorsal leptomeninges of the cervical and thoracic and lumbar spine (e.g., involving the nerve roots of the cauda equina) [Figure 1]. A loculated ventral fluid collection within the spinal canal between T12 down to L1-L2 markedly compressed the conus posteriorly [Figure 2]. Another loculated fluid collection was located dorsally at the T8-T12 thoracic spine.

Surgery

The patient underwent an emergent laminectomy from T10 to L2. No epidural abscess was seen, but the thecal sac appeared tense. A durotomy started at the L2 level and extended superiorly revealed a lobulated lesion in the intradural space and terminal filum. This phlegmon was

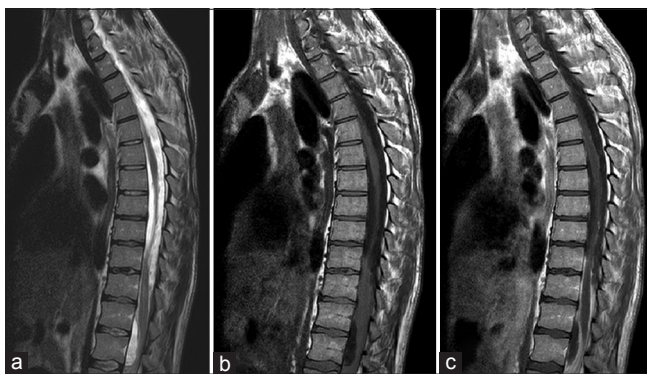

Figure 1: (a) T2 sagittal MRI: extensive loculated fluid collections compressing the spinal cord ventrally at T12-L2 and dorsally at T8-T12 level. Note T2 cord signal change within the distal thoracic cord/conus at T11-T12. (b) T1 sagittal MRI without contrast: anterior displacement of the cord from T9-T12 level. (c) T1 Sagittal MRI with contrast: distinct enhancement of the fluid collections at T8-T12, T12-L2 and leptomeninges/nerve roots in the cauda equina

tightly attached to the spinal cord and neighboring nerve roots by fibrotic gliotic tissue [Figure 3]. It was partially dissected off the spinal cord and sent for pathology and cultures. A separate durotomy at T10 ensured adequate decompression/drainage of the organized abscess.

Pathology

Histologic examination showed an organized abscess (e.g., marked infiltration of plasma and lymphocytes). Although the gram and acid-fast bacilli (AFB) stains were negative, as were the cultures, the patient was presumptively started on a 6-week course of vancomycin and ertapenem. At 6-week follow-up, his weakness remained stable but his back pain resolved. Furthermore, the white blood cell count was normal. A follow-up MR was not available at this time.

DISCUSSION

Spinal subdural empyema is rare and is typically attributed to *Staphylococcus aureus* (over 50% of cases).^[4] Other organisms may include *Streptococcus* species, *Escherichia coli*, and various anaerobes.

Four mechanisms contribute to the development of these lesions; direct spread of infection can occur secondary

Table 1: Radiographic and laboratory work up of patient's second presentation at our institution

Radiographic/Laboratory testing	Result
White blood cell counts	Within normal limits
C-reactive protein	5.3 mg/L (normal: <3.0 mg/L)
Erythrocyte sedimentation rate	44 mm/h (normal: <15 mm/h)
Blood culture	Negative
Urine culture	Negative
Echocardiogram	Negative
Computerized tomography	Hypodensity at the thoracolumbar junction

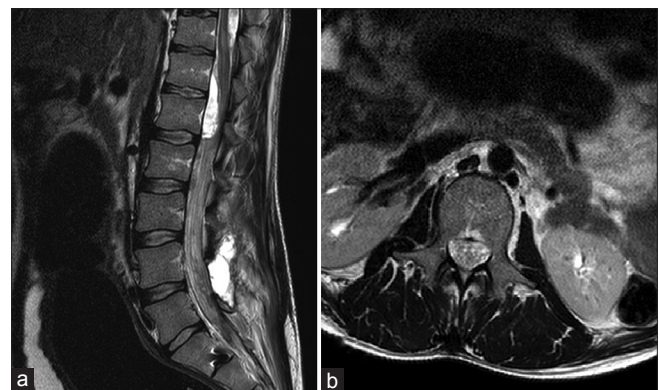


Figure 2: (a) T2 sagittal MRI: high signal fluid collection compressing/displacing the conus posteriorly. Note the irregularly thickened/clumped together nerve roots. (b) T2 sagittal MRI: irregularly thickened/clumped together nerve roots of the cauda equina

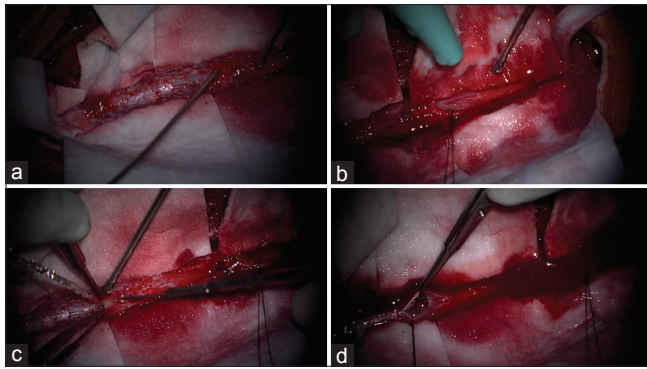


Figure 3: Intraoperative images. (a) Tense, thickened dura without any epidural abscess. (b) The dural opening at L2 showed nerve root clumping with very little cerebrospinal fluid egress/phlegmon. (c) Second dural opening at T10 showed purulent discharge. (d) Intradural spinal cord thickening/adhesions

to congenital deformities (dysraphism), hematogenous spread from a distant site, iatrogenic contamination of the subdural space (33%), and/or contiguous spread from adjacent infection.

Symptoms of chronic subdural abscesses are typically nonspecific and sometimes even absent.^[3] These most typically involve the lumbar spine with superior extension into the lower thoracic region^[4-6] The best diagnostic study is an enhanced high-resolution MRI scan, Nevertheless, the distinction between an epidural and subdural abscess remains challenging.

Although the best practice for treating subdural infections has not been well-established, the goals of surgical washout include lowering the infectious burden and obtaining culture diagnosis. Furthermore, most decompressions include consecutive or “skip” laminectomies with consecutive or skip durotomies

to ensure adequate debridement of these potentially extensive lesions.

CONCLUSION

Diabetes, intravenous drug abuse (IVDA), and immunocompromise are known risk factors for a spinal subdural abscess. This diagnosis should be considered if patients present with evidence of infection. Contrast-enhanced high-resolution MRI scans of the entire neuraxis allow the surgeon to distinguish between subdural and epidural lesions. These should be promptly explored, decompressed/washed out, and followed with appropriate long-term antibiotic treatment.

Financial support and sponsorship

Nil.

Conflicts of interest

There are no conflicts of interest.

REFERENCES

1. Diehn FE. Imaging of spine infection. *Radiol Clin North Am* 2012;50:777-98.
2. Semlali S, Akjouj S, Chaouir S, Hanine A, Ben Ameer M. Spinal subdural tuberculous abscess in a patient with tuberculous meningitis. *J Radiol* 2007;88:280-1.
3. Sorar M, Er U, Seckin H, Ozturk MH, Bavbek M. Spinal subdural abscess: A rare cause of low back pain. *J Clin Neurosci* 2008;15:292-4.
4. Velissaris D, Aretha D, Fligou F, Filos KS. Spinal Subdural *Staphylococcus Aureus* Abscess: Case report and review of the literature. *World J Emerg Surg* 2009;4:31.
5. Vural M, Arslantas A, Adapinar B, Kiremitci A, Usluer G, Cuong B, et al. Spinal subdural *Staphylococcus aureus* abscess: Case report and review of the literature. *Acta Neurol Scand* 2005;112:343-6.
6. Zemmoura I, Hamlat A, Morandi X. Intradural extramedullary spinal inflammatory myofibroblastic tumor: Case report and literature review. *Eur Spine J* 2011;20(Suppl 2):S330-5.