

Henry Ford Health

## Henry Ford Health Scholarly Commons

---

Ophthalmology Articles

Ophthalmology and Eye Care Services

---

1-23-2023

### **Benign yellow-dot maculopathy: case report and review of the literature.**

Venkatkrish M. Kasetty

Tejas U. Desai

Uday R. Desai

Follow this and additional works at: [https://scholarlycommons.henryford.com/ophthalmology\\_articles](https://scholarlycommons.henryford.com/ophthalmology_articles)

---

## Benign yellow-dot maculopathy: case report and review of the literature

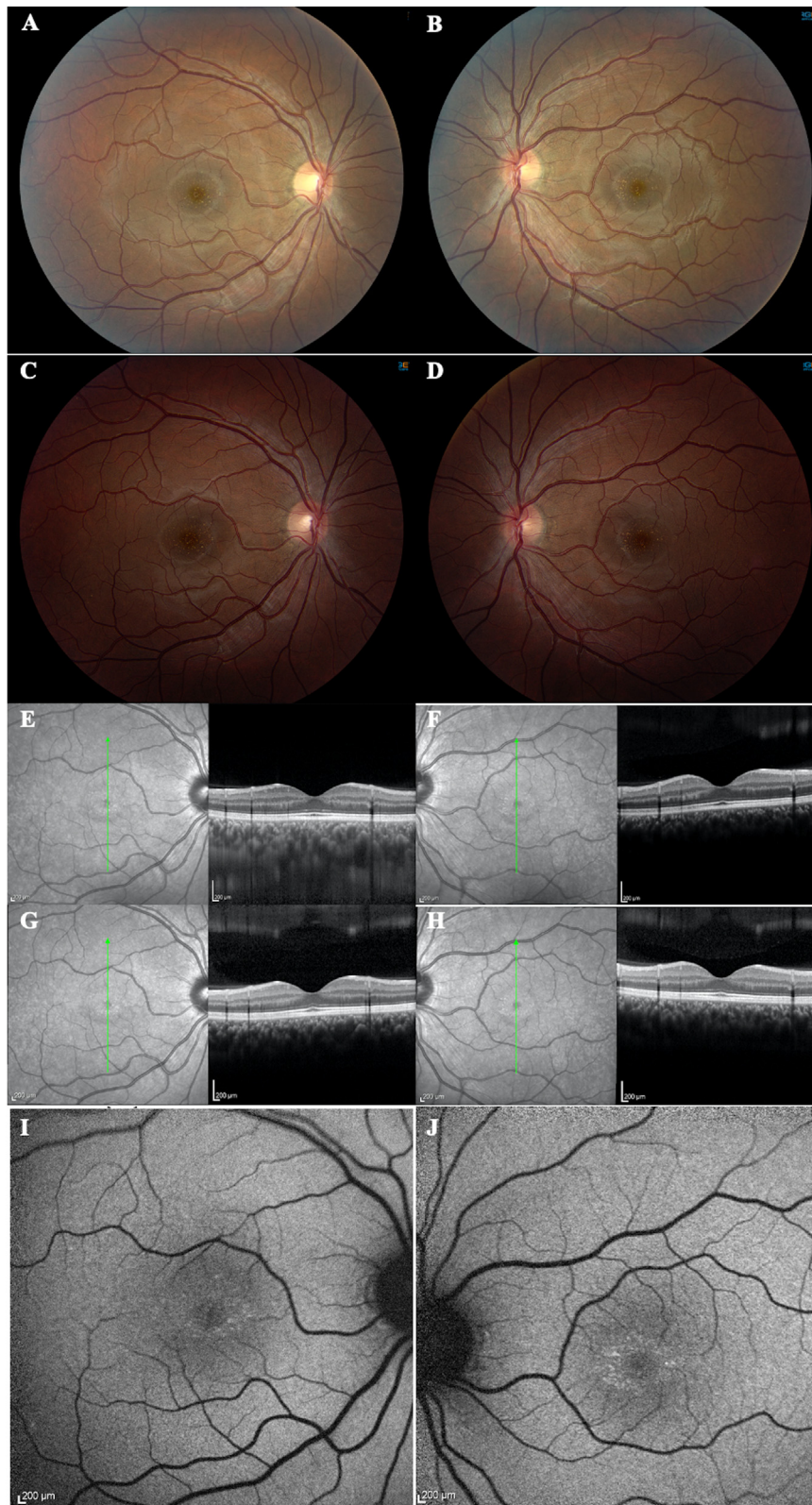
The differential diagnosis for yellow macular dots is extensive and includes toxic, genetic, degenerative, and idiopathic etiologies. In many cases, these conditions are progressive, result in decreased central visual acuity, and can be associated with systemic findings. A thorough history, examination, and multimodal visualization techniques, including optical coherence tomography (OCT), fluorescein angiography (FA), and fundus autofluorescence (FAF), are often used to diagnose these conditions.<sup>1</sup> Benign yellow-dot maculopathy, however, is a recently characterized asymptomatic, typically bilateral macular phenotype.<sup>2</sup> To our knowledge, only 45 cases from 28 families in 5 reports that have been described in the literature. Thus far there is no definite etiology of this condition, but it appears to have a sporadic or autosomal-dominant inheritance pattern without an identified causative gene.<sup>2–6</sup> Herein we describe another case of benign yellow-dot maculopathy in a young Hispanic male who remained stable through 2-year follow-up and review the literature surrounding this rare entity.

A 17-year-old Hispanic male was referred to the retina clinic for evaluation of a possible macular dystrophy. He had no visual complaints, and his past ocular history was significant for mild myopia in both eyes. His past medical history was significant for depression treated with aripiprazole. He also had a history of a suicide attempt 3 years earlier after ingesting approximately 75 Aspirin tablets and 5 aripiprazole tablets. He had no history of intravenous drug use. His family history was nonrevealing for any inherited ocular disorders. His best-corrected visual acuity (BCVA) was 20/20 in both eyes with normal intraocular pressures and no relative afferent pupillary defect. Visual fields, ocular motility, and anterior-segment examination were unremarkable. His funduscopy examination revealed multiple perifoveal fine, discrete yellow spots bilaterally (Fig. 1A, B). The retinal periphery was unremarkable. OCT was normal bilaterally (Fig. 1E, F). Because the patient was asymptomatic, he was observed with no electroretinography (ERG) or FA. On examination 2 years later, the patient's BCVA remained 20/20. He remained asymptomatic, and his fundus examination (Fig. 1C, D) and OCT images (Fig. 1G, H) remained stable. FAF demonstrated hyper-autofluorescent foci corresponding to the yellow lesions seen on clinical examination (Fig. 1I, J). No further work-up, including genetic testing, was pursued.

The differential diagnosis for yellow dots within the macula includes drug toxicities (e.g., canthaxanthin), inherited diseases (e.g., oxalosis, Bietti crystalline dystrophy), degenerative (e.g., drupelets or medium-sized drusen seen in age-related macular degeneration), and idiopathic conditions.<sup>1,7,8</sup> Degenerative changes such as drupelets

would be unlikely given the symmetrical foveal location, the age of the patient, and the normal OCT images and hyper-autofluorescence seen on FAF.<sup>8,9</sup> Because the patient did not have a known family history of retinal disease, a toxic etiology was initially considered given the recent Aspirin and aripiprazole overdose, but neither have been reported to cause crystalline retinopathy.<sup>10,11</sup> However, after 2 years of follow-up, these findings were seen to be more characteristic of a recently described phenotype—benign yellow-dot maculopathy. Borman et al.<sup>2</sup> described a series of 36 patients from 23 unique families in the initial report of benign yellow-dot maculopathy in 2017. In their report, 33 of 36 patients were asymptomatic, with the other 3 patients experiencing visual symptoms that were not attributable to these macular findings. Funduscopy findings included bilateral discrete yellow dots at the level of the retinal pigment epithelium (RPE). Additionally, these dots tended to be evenly distributed around the fovea or in the nasal parafoveal region. There were no other retinal findings.<sup>2</sup> Since this report, 9 additional cases have been described with similar presentations,<sup>4–6</sup> with Mishra et al. describing the first case of unilateral benign yellow-dot maculopathy.<sup>3</sup>

Our patient shared similar characteristics with those described in the literature, such as bilateral nonprogressive maculopathy, no visual impairments, and multiple yellow dots evenly distributed in the perifoveal macula. In the 45 cases described in the literature, the median age of the patients was 16 years (range, 5–69 years), which is like our patient's age on initial presentation. This phenotype favoured females (67%) versus males (33%). BCVA was excellent overall in these patients, with 64% of eyes having 20/20 vision (Table 1). Ophthalmic imaging findings are essential when evaluating these rare macular phenotypes. In the cases described in the literature, OCT of the macula was performed in 58% and was normal in 58% and showed ellipsoid zone irregularity in 23% and RPE irregularity in 19%. FA was only obtained in 13% of patients and revealed early hyperfluorescence of the dots (50%), normal FA (33%), and mild unilateral RPE irregularities with window defect (17%). FAF was obtained in 64% of patients, and all showed hyper-autofluorescence of the dots. ERG was obtained in 49% of patients, and all were normal except from 1 patient who was mildly abnormal. Pattern ERG was abnormal in 2 of these patients. Our patient's unremarkable OCT findings and hyper-autofluorescent dots on FAF were similar to those of the other patients described in the literature. It is likely that these hyper-autofluorescent dots on FAF are due to photoreceptor and RPE dysfunction that has been previously reported. Because of the size and non-progressive nature of these dots, the focal changes in the photoreceptors and RPE are unlikely to be visually significant and undetectable on many of our imaging modalities, which explains the unremarkable imaging findings reported in the



**Fig. 1—Fundus photography of right (A) and left eyes (B) on initial presentation. Fundus photography of right (C) and left eyes (D) at repeat examination 2 years after initial examination revealing stable yellow dots in both maculae. Unremarkable optical coherence tomography of the maculae of the right (E) and left eyes (F) on initial examination. Optical coherence tomography of the maculae of the right (G) and left eyes (H) remaining unchanged at repeat examination 2 years after the initial examination. Fundus autofluorescence revealing hyper-autofluorescent dots in both maculae on repeat examination in the right (I) and left eyes (J)**

**Table 1—Summary of demographic data of patients presenting with benign yellow-dot maculopathy in the literature**

Case number	Author(s)	Age	Family	Sex	BCVA OD (LogMAR)	BCVA OS (logMAR)
1	Borman et al. <sup>2</sup>	5	1	F	0	0
2	Borman et al. <sup>2</sup>	28	1	F	0	-0.08
3	Borman et al. <sup>2</sup>	50	1	F	-0.08	-0.08
4	Borman et al. <sup>2</sup>	14	2	M	-0.08	0
5	Borman et al. <sup>2</sup>	43	2	F	0.18	0.18
6	Borman et al. <sup>2</sup>	45	3	F	-0.08	-0.08
7	Borman et al. <sup>2</sup>	6	3	M	-0.08	-0.08
8	Borman et al. <sup>2</sup>	15	4	F	0.78	0.78
9	Borman et al. <sup>2</sup>	18	4	F	0	0
10	Borman et al. <sup>2</sup>	45	4	F	0.18	0.18
11	Borman et al. <sup>2</sup>	10	4	M	-0.08	-0.08
12	Borman et al. <sup>2</sup>	22	5	F	-0.08	-0.08
13	Borman et al. <sup>2</sup>	—	5	F	0	0
14	Borman et al. <sup>2</sup>	7	6	F	0	0
15	Borman et al. <sup>2</sup>	—	6	M	—	—
16	Borman et al. <sup>2</sup>	59	6	F	—	—
17	Borman et al. <sup>2</sup>	11	7	F	0	0
18	Borman et al. <sup>2</sup>	—	7	M	—	—
19	Borman et al. <sup>2</sup>	7	8	F	0	0
20	Borman et al. <sup>2</sup>	45	8	F	0	0
21	Borman et al. <sup>2</sup>	13	8	M	0	0
22	Borman et al. <sup>2</sup>	8	9	F	0	0
23	Borman et al. <sup>2</sup>	6	10	M	0.7	0.8
24	Borman et al. <sup>2</sup>	10	11	F	0	0
25	Borman et al. <sup>2</sup>	5	12	F	0	0
26	Borman et al. <sup>2</sup>	10	13	F	0	0
27	Borman et al. <sup>2</sup>	12	14	F	0.4	0
28	Borman et al. <sup>2</sup>	14	15	M	0.08	0.14
29	Borman et al. <sup>2</sup>	15	16	F	0	0
30	Borman et al. <sup>2</sup>	15	17	M	0	0
31	Borman et al. <sup>2</sup>	28	18	M	0	0
32	Borman et al. <sup>2</sup>	28	19	F	-0.08	-0.08
33	Borman et al. <sup>2</sup>	29	20	F	0	0
34	Borman et al. <sup>2</sup>	8	21	F	0	0
35	Borman et al. <sup>2</sup>	16	22	F	0	0
36	Borman et al. <sup>2</sup>	5.5	23	F	0	0
37	Murro et al. <sup>5</sup>	43	24	M	0	0
38	Murro et al. <sup>5</sup>	34	24	M	0	0
39	Murro et al. <sup>5</sup>	69	24	F	0	0
40	Murro et al. <sup>5</sup>	55	25	M	0	0
41	Murro et al. <sup>5</sup>	53	25	F	0	0
42	Mishra et al. <sup>5,*</sup>	25	26	M	0	0
43	Moisseiev <sup>4</sup>	24	27	M	0.1	0
44	Moisseiev <sup>4</sup>	—	27	F	0	0
45	Ninet et al. <sup>6</sup>	38	28	F	0	0
46	This study	17	29	M	0	0

BCVA, best-corrected visual acuity

\*Unilateral presentation only in the right eye.

literature. Demographically, our patient is a Hispanic male, and this has not yet been described in the literature.<sup>2–6</sup>

Limitations of this report include the single case, the lack of ophthalmic examinations prior to the Aspirin overdose, and the lack of the examinations of family members. Because this phenotype is typically asymptomatic, it is possible that our patient's family members have similar findings that have previously gone undiagnosed, especially without routine examination. Genetic testing was not performed, which may have helped elucidate a specific causative gene locus.

In conclusion, there is a paucity of literature on benign yellow-dot maculopathy. Including our case, only 46 total cases have been described in the literature to date. It is possible that this entity is underreported in the literature because patients may not present for routine examination given that they are typically asymptomatic. Because no

known etiology has been described thus far, we recommend examining family members of patients presenting with this phenotype, obtaining a thorough history of the patient and his or her family, and considering genetic testing. While this condition has not been shown to significantly affect visual acuity, we believe that it is important to increase awareness of this phenotype, allowing ophthalmologists to keep this in the differential diagnosis when evaluating patients with similar presentations and to prevent misdiagnosis.

**Venkatkrish M. Kasetty, Tejas U. Desai, Uday R. Desai**

Henry Ford Health System, Detroit, MI.

Originally received Aug. 29, 2022. Final revision Dec. 20, 2022. Accepted Jan. 6, 2023.

Correspondence to Venkatkrish M. Kasetty, MD; vkasett1@hfhs.org.

## References

---

1. Kovach JL, Isildak H, Sarraf D. Crystalline retinopathy: unifying pathogenic pathways of disease. *Surv Ophthalmol* 2019;64:1–29.
2. Borman AD, Rachitskaya A, Suzani M, et al. Benign yellow dot maculopathy: a new macular phenotype. *Ophthalmology* 2017;124:1004–13.
3. Mishra AV, Pollmann AS, Choudhry N, Demmings E, Gupta RR. Unilateral benign yellow dot maculopathy. *Am J Ophthalmol Case Rep* 2021;22:101068.
4. Moisseiev E. Benign yellow dot maculopathy. *Am J Ophthalmol Case Rep* 2018;10:13–5.
5. Murro V, Mucciolo DP, Giorgio D, et al. Multimodal imaging of benign yellow dot maculopathy. *Ophthalmic Genet* 2019;40:135–40.
6. Ninet L, David T, Gascon P. Multimodal imaging for benign yellow dot maculopathy. *Ophthalmol Retina* 2022;6:307.
7. Dreenser K, Sarraf D, Jain A, Small KW. Crystalline retinopathies. *Surv Ophthalmol* 2006;51:535–49.
8. Ferris 3rd FL, Wilkinson CP, Bird A, et al. Clinical classification of age-related macular degeneration. *Ophthalmology* 2013;120:844–51.
9. Ly A, Nivison-Smith L, Assaad N, Kalloniatis M. Fundus autofluorescence in age-related macular degeneration. *Optom Vis Sci* 2017;94:246–59.
10. Faure C, Audo I, Zeitz C, Letessier JB, Robert MP. Aripiprazole-induced chorioretinopathy: multimodal imaging and electrophysiological features. *Doc Ophthalmol* 2015;131:35–41.
11. Zhu W, Wu Y, Xu D, et al. Aspirin use and risk of age-related macular degeneration: a meta-analysis. *PLoS ONE* 2013;8:e58821.

## Footnotes and Disclosure

---

The authors have no proprietary or commercial interest in any materials discussed in this correspondence.