

Henry Ford Health

Henry Ford Health Scholarly Commons

Women's Health Articles

Obstetrics, Gynecology and Women's Health
Services

4-1-2022

A multidisciplinary approach to caring for a pregnant patient with blue rubber bleb nevus syndrome: A case report

Sydney Daviskiba

Hannah Shuman

Mariam Ayyash

Gayathri Vadlamudi


Stefan Smietana

See next page for additional authors

Follow this and additional works at: https://scholarlycommons.henryford.com/womenshealth_articles

Authors

Sydney Daviskiba, Hannah Shuman, Mariam Ayyash, Gayathri Vadlamudi, Stefan Smietana, and Gregory Goyert



A multidisciplinary approach to caring for a pregnant patient with blue rubber bleb nevus syndrome: A case report

Sydney Daviskiba^a, Hannah Shuman^a, Mariam Ayyash^{b,*}, Gayathri Vadlamudi^b, Stefan Smietana^b, Gregory Goyert^c

^a Wayne State University School of Medicine, Detroit, MI, United States of America

^b Department of Obstetrics and Gynecology, Henry Ford Hospital, Detroit, MI, United States of America

^c Division of Maternal and Fetal Medicine, Department of Obstetrics and Gynecology, Henry Ford Hospital, Detroit, MI, United States of America

ARTICLE INFO

Keywords:

Rare disorders
Syndromes
Pregnancy
Morbidity
Antepartum management

ABSTRACT

Blue rubber bleb nevus syndrome (BRBNS) is a rare vascular disorder characterized by recurrent, multifocal venous malformations throughout the skin, soft tissue, and numerous internal organs. Pregnant women with BRBNS are at high risk of morbidity and mortality, and thus their care requires careful planning and surveillance. This report highlights the case of a 21-year-old woman, gravida 1, para 0, with BRBNS who was cared for by a multidisciplinary team of providers in obstetrics, maternal-fetal medicine, obstetric anesthesia, hematology, dermatology, gastroenterology, and otorhinolaryngology. The report provides a comprehensive guide to the multidisciplinary management of pregnancy and delivery for patients with BRBNS.

1. Introduction

Blue rubber bleb nevus syndrome (BRBNS) is a rare vascular disorder characterized by recurrent, multifocal venous malformations (VMs) throughout the skin, soft tissue, and internal organs [1]. These VMs have a high likelihood of bleeding and, as such, patients with BRBNS frequently develop gastrointestinal (GI) bleeding and chronic anemia, often requiring transfusion of blood products. While the exact etiology of BRBNS is not clear, most cases occur sporadically, while some familial cases with autosomal dominant inheritance have been noted [2–4]. Approximately 200 cases of BRBNS have been published in the literature with a very small subset documented among pregnant women [5–16]. Reports of BRBNS in pregnant women have described the presence of VMs in several locations, such as the GI tract, central nervous system, airway, spinal epidural space, vaginal vault, and anterior abdominal wall, creating obstetrical concerns that require consultation with physicians of numerous specialties. To date, no comprehensive guide detailing the care and necessary interventions for pregnant patients with BRBNS has been published.

This report represents the case of a 21-year-old woman with a history of BRBNS whose pregnancy was complicated by severe, symptomatic anemia as a result of her disease process. It serves as a guide for the multidisciplinary management of prenatal and intrapartum BRBNS

when caring for pregnant patients.

2. Case Presentation

A 21-year-old woman, gravida 1, para 0, with BRBNS since childhood presented for prenatal care at 17 weeks and 5 days of gestation. She was diagnosed with BRBNS at the age of 6 with no family members affected by this syndrome. She had a history of GI bleeding complicated by chronic iron deficiency anemia requiring blood transfusions and had undergone more than 20 surgeries in her lifetime for resection of extensive cutaneous and GI VMs. The patient's care was coordinated via the hospital's multidisciplinary Maternal Critical Care Conference because of the complexity involved in planning her prenatal care and delivery with respect to BRBNS. The multidisciplinary team included experts in obstetrics, maternal-fetal medicine, obstetric anesthesia, hematology, dermatology, gastroenterology, and otorhinolaryngology.

Early consultation with obstetric anesthesia was prioritized to assess for spinal or airway involvement of disease and to begin planning the intrapartum analgesia and mode of delivery. Non-contrast magnetic resonance imaging of the spine revealed lesions that appeared to be VMs in the T1-T2 and L4-L5 epidural space (Fig. 1). Bedside flexible nasopharyngolaryngoscopy performed by an otolaryngologist was grossly unremarkable, but assessment past the subglottis was not possible. As

* Corresponding author at: Department of Obstetrics and Gynecology, Henry Ford Hospital, 2799 W. Grand Blvd, Detroit, MI 48202, United States of America.
E-mail address: mayyash1@hfhs.org (M. Ayyash).

<https://doi.org/10.1016/j.crwh.2022.e00403>

Received 6 February 2022; Received in revised form 6 March 2022; Accepted 7 March 2022

Available online 9 March 2022

2214-9112/Published by Elsevier B.V. This is an open access article under the CC BY-NC-ND license (<http://creativecommons.org/licenses/by-nc-nd/4.0/>).

such, despite the suspected epidural involvement, anesthesiologists recommended that the patient receive ultrasound-guided neuraxial analgesia at the time of delivery to avoid the risks of intubation. Additional consultations were done with dermatology and gastroenterology physicians. Dermatologists did not recommend any interventions. Although gastroenterologists planned for video capsule endoscopy to assess the patient's pre-existing gastric, duodenal, and jejunal VMs (Fig. 2), she was unable to attend the procedure.

The patient's pregnancy was complicated by a hospital admission at 26 weeks of gestation for blood transfusion to treat severe symptomatic anemia (hemoglobin 5.6 g/dL; baseline hemoglobin 7.5 g/dL), which was found during routine prenatal laboratory testing. Her symptoms improved and her hemoglobin returned to near baseline (7.2 g/dL) after she received 2 units of packed red blood cells and intravenous iron. Hematologists recommended that she receive intravenous iron infusions every 2 to 4 weeks in addition to her current regimen of oral iron tablets and prenatal vitamins.

The patient presented to labor and delivery at 39 weeks and 4 days of gestation with contractions and worsening respiratory symptoms from confirmed COVID-19. Fetal heart tracing was overall reassuring, and the fetus was cephalic. Induction of labor was initiated with the placement of a cervical Foley catheter. The patient developed worsening maternal tachycardia with increasing need for oxygen supplementation and fetal tachycardia to 180 beats per minute with intermittent late decelerations. Because of the non-reassuring fetal heart rate tracing in the setting of the worsening respiratory symptoms from COVID-19, the patient underwent a low transverse cesarean delivery. Given the acuity of the patient's clinical presentation and need for urgent cesarean delivery, general anesthesia was administered with uncomplicated intubation. Her recovery was uncomplicated, she no longer required oxygen supplementation, and she was discharged home on postoperative day 2. The infant weighed 3135 g and had Apgar scores of 3, 5, and 9 at 1, 5, and 10 min, respectively, and was discharged home with the patient.

3. Discussion

Management of BRBNS can be challenging, and complications may be compounded by pregnancy. Literature on the management of BRBNS in pregnancy is rare. Documented complications of BRBNS in pregnant patients have included involvement of the vaginal vault prohibiting a vaginal delivery [5], airway and neuraxial compromise with contraindications to epidural anesthesia [6], pulmonary embolism [7], severe GI bleeding requiring laparotomy and small bowel resection [8], acute intestinal intussusception complicated by postoperative disseminated intravascular coagulation [9], anterior abdominal wall involvement resulting in hemorrhage during cesarean delivery [17], and hemorrhage and consumptive coagulopathy of the affected neonate [10]. Because of the breadth of potential complications associated with BRBNS, a multidisciplinary approach to prenatal and intrapartum care is necessary. Table 1 summarizes key details of the comprehensive approach to

caring for pregnant women with BRBNS. Notably, social support is exceptionally important, since untreated complications from inadequate follow-up greatly increase risk of morbidity and mortality for both mother and fetus.

The recommended multidisciplinary approach includes collaboration between several specialists, including maternal-fetal medicine, obstetric anesthesia, otorhinolaryngology, gastroenterology, hematology, and dermatology, along with neonatology at the time of delivery. Ideally, this collaboration should take place prior to conception for optimization of maternal health status before pregnancy. While neurological care was not necessary for this patient, Galey et al. consulted neurosurgery for further evaluation of a patient who had spinal involvement from BRBNS. Neurological complications may be seen in patients when BRBNS manifests neuraxially and in the central nervous system, necessitating consultation with a neurosurgeon [6]. Social services should be involved as needed to assist with any potential social barriers to care.

Patients with BRBNS should continue to receive routine prenatal care and monitoring for commonly encountered obstetric complications. Liu et al. highlight the importance of monitoring for routine obstetric risks in the case of a patient with BRBNS who went on to develop a pulmonary embolism [7]. Despite the increased risk of bleeding from VMs, the hypercoagulable state of pregnancy still places pregnant patients with BRBNS at increased risk of venous thromboembolism, and these individuals should be monitored as such. In addition to receiving routine prenatal care and monitoring, patients should be referred to maternal-fetal medicine and their cases discussed at monthly collaborative maternal critical care conferences to create an evolving plan for prenatal care and delivery. It is imperative for patients with BRBNS to receive early evaluation by obstetric-anesthesiology experts to plan for a method of intrapartum anesthesia, and they should undergo an airway assessment by otorhinolaryngology. Additionally, magnetic resonance imaging of the entire spine should be performed to assess for VMs in the spinal canal, which may be a contraindication to neuraxial analgesia during labor and delivery. Weighing the risks of intubation and general anesthesia versus possible epidural bleeding in patients with BRBNS spinal involvement is critical. Ultrasound-guided epidural placement was initially recommended for the patient before urgent cesarean delivery became necessary. Use of imaging during epidural placement may be a safer compromise for patients with neuraxial VMs and unknown airway involvement that may complicate intubation under general anesthesia.

Reports by Orchiai et al. and Kanai et al. suggest that pregnancy may exacerbate BRBNS, with increased VM size and risk of bleeding from existing VMs, as well as development of VMs at new sites [2,8]. As such, reassessing preexisting VMs in consultation with dermatology and gastroenterology and performing serial speculum exams to assess for involvement of the vaginal vault are key aspects of care. Galey et al. also assessed their patient for the presence of VMs in the pelvic region using magnetic resonance imaging [6]. Furthermore, as many patients with

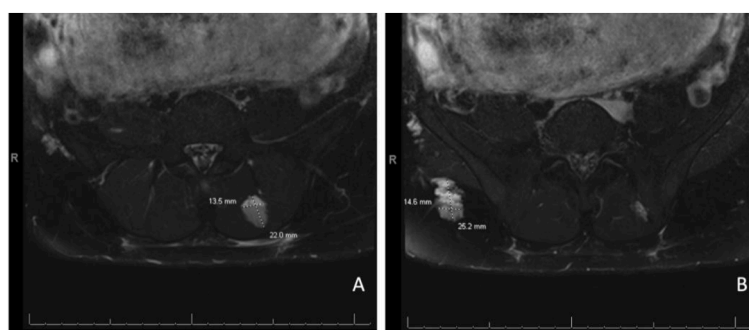


Fig. 1. Magnetic resonance imaging without contrast of lumbar spine showing lesions indicating venous malformations (A) at L4-L5 and (B) within the subcutaneous fat of the right buttock.

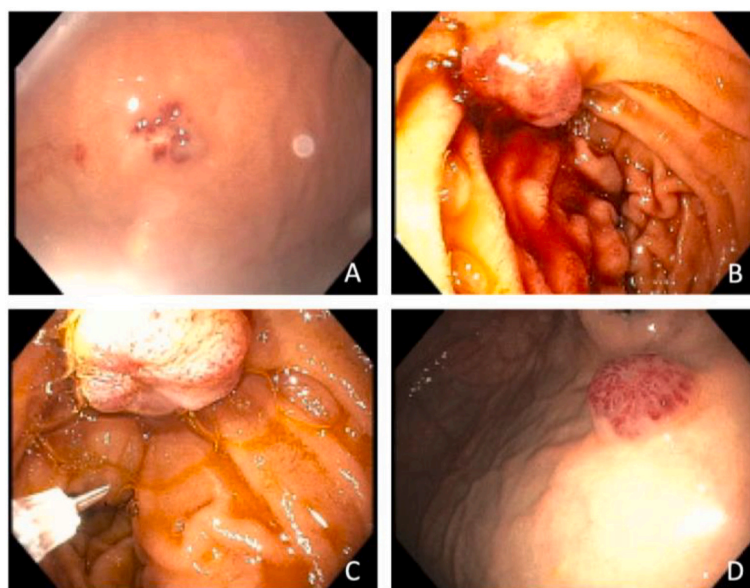


Fig. 2. Esophagogastroduodenoscopy (prior to conception) showing venous malformations in the (A) lesser curvature of the stomach, (B and C) second portion of the duodenum, and (D) antrum of the stomach.

Table 1
Summary of multidisciplinary prenatal care organized by subspecialty.

Specialty	Recommendations
Obstetrics & Maternal - Fetal Medicine	Routine prenatal care and monitoring Monthly multidisciplinary maternal critical care conferences Formal fetal ultrasonography evaluation Weekly non-stress tests at 32 weeks (individualized recommendation pending other comorbidities) Assessment of vaginal canal with serial speculum exam (repeat before induction of labor if planning vaginal delivery) Determine mode of delivery (vaginal vs. cesarean) Schedule delivery at 39 weeks
Obstetric Anesthesia	Assessment for epidural/paraspinal VMs with non-contrast spinal magnetic resonance imaging Consider intrapartum arterial line for hemodynamic monitoring Determine method of intrapartum anesthesia (neuraxial vs. general) Consider use of ultrasound guidance for epidural placement Consider intraoperative blood salvage
Otorhinolaryngology	Assess airway for mucosal VMs, which increase risk during intubation Otorhinolaryngology experts present for intubation if general anesthesia is required
Gastroenterology	Assess for active bleeding of VMs with video capsule endoscopy
Dermatology	Assess cutaneous VMs Excise actively bleeding lesions when present
Hematology	Routine monitoring of complete blood count Maternal screening for hematologic antibodies Iron replacement, as needed Transfusion blood products screened for hematologic antigens, as needed Blood bank coordination
Neonatology	Prenatal assessment in case of fetal BRBNS findings on ultrasonography Present during delivery for immediate evaluation of neonate
Neurosurgery	Evaluation of central nervous system and epidural space for VMs, as needed
Social Work	Assistance for social barriers to care that may prevent follow-up (example, transportation, insurance, etc.)

BRBNS, blue rubber bleb nevus syndrome; VM, venous malformation.

BRBNS have a history of numerous blood transfusions, they may have an increased risk for the presence of antibodies and fetal isoimmunization. These patients should be screened for the presence of such antibodies, with additional screening of the father of the baby if antibodies are detected in the mother. In the case of maternal antibody detection, close communication with hospital blood banks should be made to ensure that blood products are being screened for antigens, and appropriate units should be held for possible use during labor to mitigate the high risk of intrapartum bleeding. Additionally, intraoperative blood salvage (cell saver) may be recommended for patients who have significant blood loss.

For fetal assessment, detailed anatomical ultrasonography should be done with prenatal neonatology consultation to evaluate for findings suggestive of fetal BRBNS. Additionally, weekly non-stress tests starting at 32 weeks are an individualized recommendation, depending on patient comorbidities. Delivery should be planned for an induction of labor or cesarean delivery (for maternal indications) at 39 weeks and should take place during daytime hours and on a weekday, when resources and personnel are most accessible. Given the high bleeding risk faced by patients with BRBNS due to multiple sources such as vaginal canal, airway, or spinal canal, delivery under controlled settings and hence a scheduled delivery can allow all teams involved in patient care to be aware and present if adverse outcomes were to present. For patients with exceptionally high risk of bleeding or complication, whether due to VMs in airway, spinal canal, or vaginal canal, delivery in a main operating room rather than a labor and delivery operating room may be appropriate. This would allow for immediate attention and safest patient outcome if anesthesia, massive transfusion, and surgical intervention were required. While delivering in the operating room can place an impact on the maternity unit at the time, these disorders are very rare and when high risk for bleeding is a concern, such location for delivery would be more ideal despite resource impact, to allow for best patient outcomes. Neonatology experts should be present at the time of delivery so that immediate evaluation of the neonate for signs and symptoms of bleeding secondary to congenital BRBNS can be performed.

In conclusion, pregnant patients who have BRBNS are at increased risk of morbidity and mortality. To best assess and plan for complications during the prenatal and perinatal care of these at-risk patients, an early multidisciplinary approach with close coordination between multiple specialties is recommended.

Contributors

Sydney Daviskiba cared for the patient throughout her labor and delivery admission, conceived the idea for the case report and wrote the manuscript.

Hannah Shuman cared for the patient throughout her labor and delivery admission, conceived the idea for the case report and wrote the manuscript.

Mariam Ayyash cared for the patient throughout her labor and delivery admission, conceived the idea for the case report, wrote the manuscript, obtained consent from the patient and revised the manuscript.

Gayathri Vadlamudi cared for the patient throughout her labor and delivery admission, conceived the idea for the case report and wrote the manuscript.

Stefan Smietana provided prenatal care for the patient throughout her pregnancy, and reviewed and edited the manuscript.

Gregory Goyert provided maternal-fetal medicine expertise care, and reviewed and edited the manuscript.

All authors approved submission of the manuscript. Sydney Daviskiba and Hannah Shuman contributed most to the writing.

Funding

This research did not receive any specific grant from funding agencies in the public, commercial, or not-for-profit sectors.

Patient consent

Consent was obtained from the patient.

Provenance and peer review

This article was not commissioned and was peer reviewed.

Acknowledgements

The authors thank Karla D. Passalacqua, PhD, at Henry Ford Hospital for her editorial assistance and Stephanie Stebens, MLIS, at Sladen Library, Henry Ford Hospital, for her input in reviewing this manuscript.

Conflict of interest statement

The authors declare that they have no conflict of interest regarding the publication of this case report.

References

- [1] D. Baigrie, A.S. Rice, I.C. An, Blue rubber bleb nevus syndrome, in: StatPearls [Internet], StatPearls Publishing, Treasure Island (FL), 2021 Jul 12, 2022 Jan–. PMID: 31082129.
- [2] D. Ochiai, K. Miyakoshi, K. Yakubo, T. Fukuiya, Y. Yoshimura, Familial blue rubber bleb nevus syndrome in pregnancy with spinal epidural involvement, Case Rep. Obstet. Gynecol. 2013 (2013), 141506, <https://doi.org/10.1155/2013/141506>.
- [3] T. Kisu, K. Yamaoka, Y. Uchida, H. Mori, T. Nakama, T. Hisatsugu, et al., A case of blue rubber bleb nevus syndrome with familial onset, Gastroenterol Jpn 21 (1986) 262–266, <https://doi.org/10.1007/BF02774569>.
- [4] S. Carvalho, V. Barbosa, N. Santos, E. Machado, Blue rubber-bleb nevus syndrome: report of a familial case with a dural arteriovenous fistula, AJNR Am. J. Neuroradiol. 24 (2003) 1916–1918.
- [5] N. Tanaka, M. Tsuda, O. Samura, H. Miyoshi, T. Hara, Y. Kudo, Blue rubber bleb nevus syndrome: report of a patient with hemangiomas of the vaginal portion of the cervix appearing during pregnancy, J. Obstet. Gynaecol. Res. 33 (2007) 546–548, <https://doi.org/10.1111/j.1447-0756.2007.00568.x>.
- [6] J. Galey, S. Bharadwaj, S. Crimmins, C.M. Hong, A.M. Malinow, Anesthetic implications of an obstetric patient with blue rubber bleb nevus syndrome, A A Case Rep 6 (2016) 146–149, <https://doi.org/10.1213/XAA.0000000000000265>.
- [7] Y.L. Liu, Y.P. Jiang, J. Du, Pulmonary embolism during pregnancy in a case of blue rubber bleb nevus syndrome, Chin. Med. J. 132 (2019) 1499–1501, <https://doi.org/10.1097/CM9.0000000000000268>.
- [8] M. Kanai, M. Noike, C. Masaki, N. Kita, T. Ashida, T. Kobayashi, I. Konishi, Severe gastrointestinal bleeding during pregnancy in a case of blue rubber bleb nevus syndrome, Semin. Thromb. Hemost. 31 (2005) 284–289, <https://doi.org/10.1055/s-2005-872433>.
- [9] C. Menegozzo, F. Novo, N.D. Mori, C.O. Bernini, E.M. Utiyama, Postoperative disseminated intravascular coagulation in a pregnant patient with blue rubber bleb nevus syndrome presenting with acute intestinal obstruction: case report and literature review, Int. J. Surg. Case Rep. 39 (2017) 235–238, <https://doi.org/10.1016/j.ijscr.2017.08.026>.
- [10] E. Monrighal, D. Gallot, I. James, F. Hameury, P. Vanlieferinghen, L. Guibaud, Venous malformation of the soft tissue associated with blue rubber bleb nevus syndrome: prenatal imaging and impact on postnatal management, Ultrasound Obstet. Gynecol. 34 (2009) 730–732, <https://doi.org/10.1002/uog.7469>.
- [11] O. Wada, N. Unno, R. Matsuoka, Y. Taketani, A case report: pregnancy complicated by blue rubber-bleb nevus syndrome, J. Obstet. Gynaecol. Res. 25 (1999) 261–263, <https://doi.org/10.1111/j.1447-0756.1999.tb01159.x>.
- [12] D.M. Nirmal, S. Rhodes, M. Hassanaeni, Pregnancy in blue rubber bleb syndrome: a case report, Am. J. Obstet. Gynecol. 199 (2008) e14–e15, <https://doi.org/10.1016/j.ajog.2008.01.028>.
- [13] H. Bouchghoul, J. Nizard, Pregnancy and blue rubber bleb nevus syndrome, Eur. J. Obstet. Gynecol. Reprod. Biol. 169 (2013) 415–416, <https://doi.org/10.1016/j.ejogrb.2013.05.009>.
- [14] M. Terata, A. Kikuchi, T. Kanasugi, A. Fukushima, T. Sugiyama, Association of blue rubber bleb nevus syndrome and placenta previa: report of a case, J. Clin. Ultrasound 41 (2013) 517–520, <https://doi.org/10.1002/jcu.22000>.
- [15] M. Hult, H. Halldorsdottir, Y. Vlado Stjernholm, A. Hein, H. Jörnval, Blue rubber bleb nevus syndrome in the obstetric patient: a case report of anesthetic implications and management, A A Pract 15 (2021), e01517, <https://doi.org/10.1213/XAA.0000000000001517>.
- [16] A.A. Adeniji, F.M. Fairlie, T.H. Jones, P. Wilkinson, Pregnancy and blue rubber bleb naevus syndrome, Br. J. Obstet. Gynaecol. 106 (1999) 1316–1318, <https://doi.org/10.1111/j.1471-0528.1999.tb08190.x>.
- [17] M. Cauldwell, P. Kyle, I. Treharne, T. Wong, S.T. Holden, C. Nelson-Piercy, Venous malformations of the anterior abdominal wall in blue rubber bleb naevus syndrome: implications for antenatal and intrapartum management, Obstet Med 4 (2011) 37–38, <https://doi.org/10.1258/om.2010.100070>.