

Henry Ford Health

Henry Ford Health Scholarly Commons

Gastroenterology Articles

Gastroenterology

2-1-2021

The use of a rescue stent in the management of lumen-apposing metal stent migration during EUS-directed transgastric ERCP with stent-in-stent technique to remove a forgotten metal biliary stent

Jessica Jou

Henry Ford Health, jjou1@hfhs.org

Andrew Watson

Henry Ford Health, awatso10@hfhs.org

Tobias Zuchelli

Henry Ford Health, TZUCHEL1@hfhs.org

Follow this and additional works at: https://scholarlycommons.henryford.com/gastroenterology_articles

Recommended Citation

Jou J, Watson A, and Zuchelli T. The use of a rescue stent in the management of lumen-apposing metal stent migration during EUS-directed transgastric ERCP with stent-in-stent technique to remove a forgotten metal biliary stent. *VideoGIE* 2021; 6(2):84-86.

This Article is brought to you for free and open access by the Gastroenterology at Henry Ford Health Scholarly Commons. It has been accepted for inclusion in Gastroenterology Articles by an authorized administrator of Henry Ford Health Scholarly Commons.



The use of a rescue stent in the management of lumen-apposing metal stent migration during EUS-directed transgastric ERCP with stent-in-stent technique to remove a forgotten metal biliary stent

Jessica Jou, MD, Andrew Watson, MD, Tobias Zuchelli, MD

Roux-en-Y gastric bypass poses a unique set of challenges during ERCP. Conventional approaches include laparoscopic-assisted ERCP and balloon-assisted enteroscopy. Laparoscopic-assisted ERCP is invasive and requires coordination between a surgeon and gastroenterologist. Balloon-assisted ERCP has a lower procedural success rate (60%-80%),¹ and the size of the working channel can limit interventions. EUS-directed transgastric ERCP (EDGE) (Fig. 1)² allows for a same-day or multistep procedure by creating a gastrogastic fistula, allowing endoscopic access to the biliary tree via the excluded stomach.³⁻⁵

A 73-year-old man with a history of Roux-en-Y gastric bypass underwent a laparoscopic-assisted ERCP and cholecystectomy 4 years earlier for choledocholithiasis. A fully

covered metal stent was placed for a narrowing in the terminal bile duct and was forgotten until the patient presented to our institution with elevated liver function tests and pain. Imaging demonstrated stent occlusion and partial migration.

Same-day EDGE was planned because the patient lived 4 hours away and was symptomatic. EUS was used to identify the remnant stomach (Fig. 2). A 19-gauge Boston Scientific Expect FNA needle was used to puncture the gastric remnant, which was filled with normal saline solution and dilute contrast to provide a larger target for lumen-apposing metal stent (LAMS) placement (Fig. 3). A Boston Scientific (Marlborough, Mass, USA) AXIOS-EC 20-mm × 10-mm LAMS was placed under fluoroscopic and endoscopic guidance and dilated to 20 mm (Fig. 4).

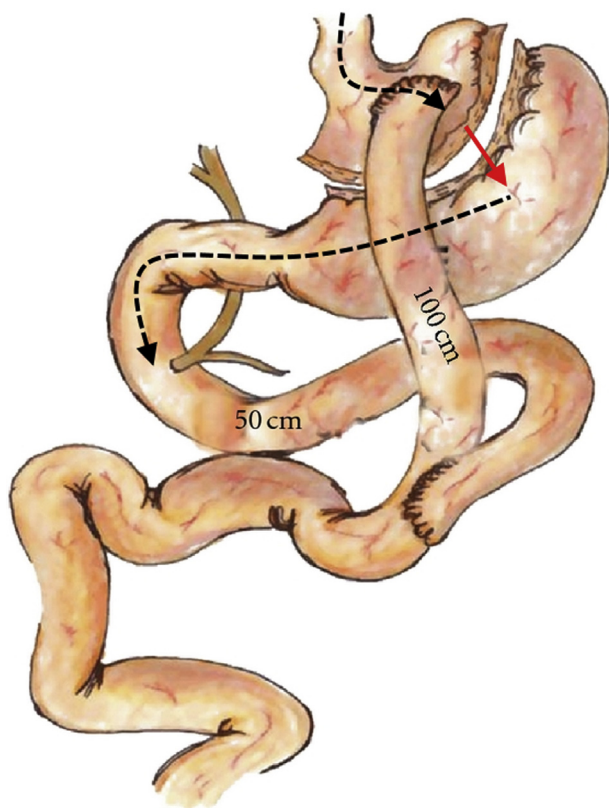


Figure 1. EUS-directed transgastric ERCP procedure.²

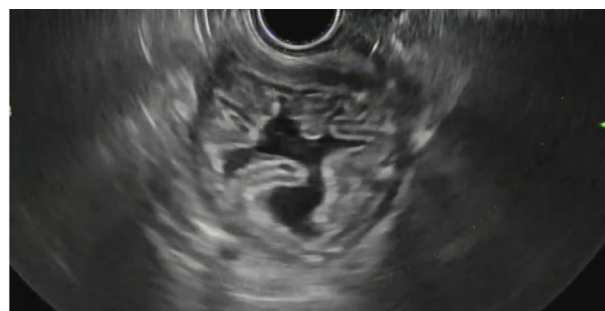

Figure 2. Identification of the remnant stomach on EUS using the sand-dollar sign.

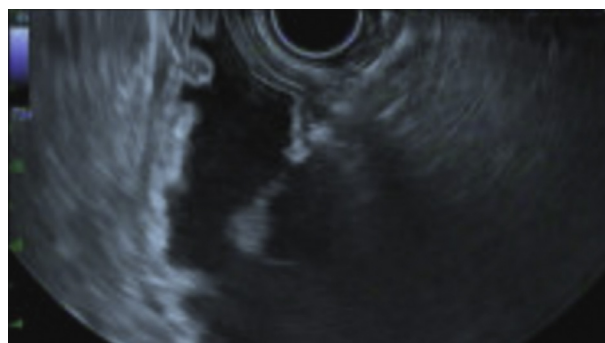

Figure 3. Expansion of the remnant stomach with the use of dilute contrast.

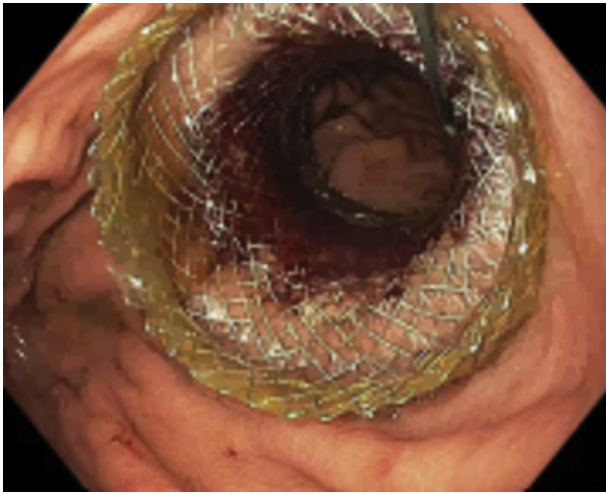


Figure 4. Endoscopic view after lumen-apposing metal stent placement, with guidewire access between the 2 stomachs.



Figure 6. Successful simultaneous removal of both biliary stents.

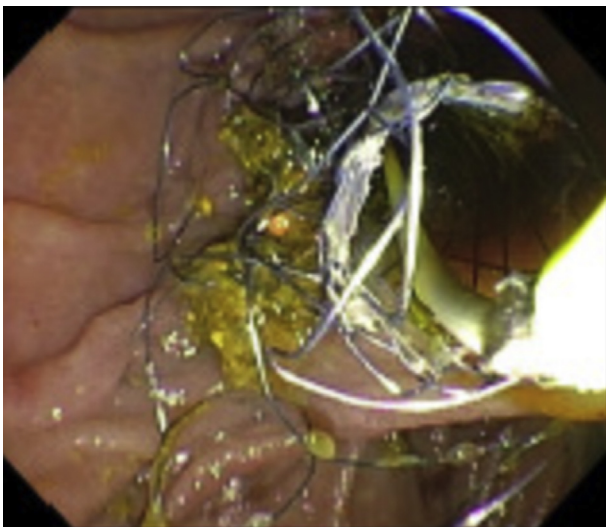


Figure 5. Placement of fully covered metal biliary stent within the indwelling biliary stent to allow for stent-in-stent removal technique.

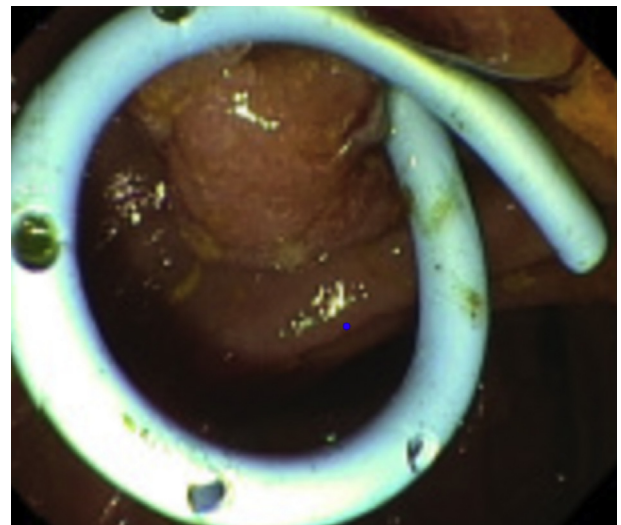


Figure 7. Placement of a plastic biliary stent after removal of indwelling biliary stent.

The stent was sutured to the gastric pouch using an Apollo overstitch to limit the risk of migration. Looping in the excluded stomach precluded passage of the duodenoscope across the pylorus, and the procedure was aborted to allow the tract to mature. After withdrawal of the duodenoscope, free air was appreciated on fluoroscopy, and endoscopic evaluation demonstrated partial dislodgement of the LAMS with associated perforation. Because guidewire access to the excluded stomach was maintained throughout the procedure, we were able to remove the LAMS, suction free fluid from the peritoneum, and place overlapping through-the-scope (TTS) Tae-Woong (Tae-Woong Medical, South Korea) 20-mm × 6-cm and 20-mm × 8-cm fully covered metal stents to bridge the perforation. Two stents were used owing to concern that the first stent did not adequately cover the

perforation. The patient was admitted for observation and was discharged the next day.

On repeat ERCP, the previously placed metal biliary stent could not be removed despite attempts with multiple devices, likely owing to stent in-growth from prolonged placement. A 10-mm × 8-cm fully covered Wallflex (Boston Scientific) metal biliary stent was placed through the indwelling biliary stent to allow for removal via the stent-in-stent technique (Fig. 5), which is thought to create pressure ischemia and necrosis of the granulation tissue, thereby facilitating removal of both stents simultaneously.⁶⁻⁸ Both stents were easily and successfully removed using a snare on follow-up ERCP and were replaced with a plastic biliary stent to ensure adequate drainage (Figs. 6 and 7).

On final ERCP, the bile duct was cleared, all stents were removed (Fig. 8), and the gastrogastic fistula was closed

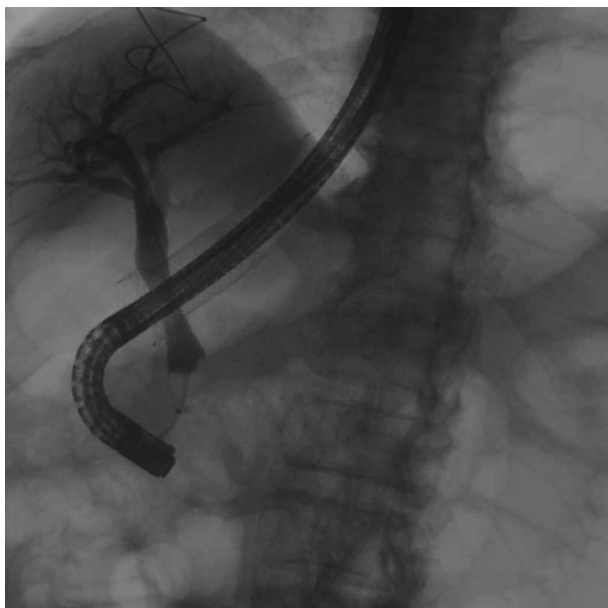


Figure 8. Final cholangiogram.

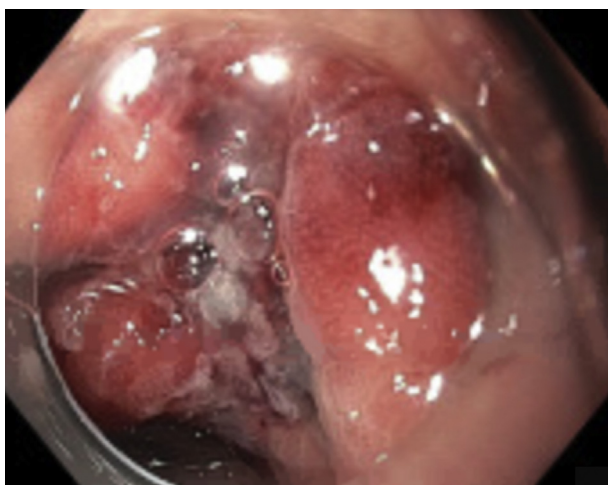

Figure 9. View after closure of the gastrogastric fistula.

via endoscopic suturing (Fig. 9). The patient did well, with no adverse events or weight regain months later.

LAMS migration is a known adverse event of EDGE, reported in 15% to 40% of cases.⁹ This can occur despite safeguards, including suturing the stent in place, and can result in GI bleeding or perforation. The use of a guidewire to maintain access between the 2 parts of the stomach can allow for intraprocedural rescue techniques, such as the use of TTS fully covered metal stents, for the management of iatrogenic perforation.¹⁰ This case highlights the use of TTS esophageal stents as a rescue

technique to treat a migrated LAMS during EDGE and the use of the stent-in-stent technique to extract a difficult-to-remove indwelling biliary stent (Video 1, available online at www.VideoGIE.org).

DISCLOSURE

Dr Zucbelli is a consultant for Boston Scientific. All other authors disclosed no financial relationships.

Abbreviations: EDGE, EUS-directed transgastric ERCP; LAMS, lumen-opposing metal stent; TTS, through the scope.

REFERENCES

1. Bukhari M, Kowalski T, Nieto J, et al. An international, multicenter, comparative trial of EUS-guided gastrogastrostomy-assisted ERCP versus enteroscopy-assisted ERCP in patients with Roux-en-Y gastric bypass anatomy. *Gastrointest Endosc* 2018;88:486-94.
2. Rizzello M, De Angelis F, Campanile FC, et al. Effect of gastrointestinal surgical manipulation on metabolic syndrome: a focus on metabolic surgery. *Gastroenterol Res Pract* 2012;2012:670418.
3. Wang TJ, Thompson CC, Ryou M. Gastric access temporary for endoscopy (GATE): a proposed algorithm for EUS-directed transgastric ERCP in gastric bypass patients. *Surg Endosc* 2019;33:2024-33.
4. Ngamruengphong S, Nieto J, Kunda R, et al. Endoscopic ultrasound-guided creation of a transgastric fistula for the management of hepatobiliary disease in patients with Roux-en-Y gastric bypass. *Endoscopy* 2017;49:549-52.
5. Kedia P, Tyberg A, Kumta NA, et al. EUS-directed transgastric ERCP for Roux-en-Y gastric bypass anatomy: a minimally invasive approach. *Gastrointest Endosc* 2015;82:560-5.
6. Tringali A, Blero D, Boškoski I, et al. Difficult removal of fully covered self expandable metal stents (SEMS) for benign biliary strictures: the "SEMS in SEMS" technique. *Dig Liver Dis* 2014;46:568-71.
7. Menon S. Removal of an embedded "covered" biliary stent by the "stent-in-stent" technique. *World J Gastroenterol* 2013;19: 6108-9.
8. Hirdes MM, Siersema PD, Houben MH, et al. Stent-in-stent technique for removal of embedded esophageal self-expanding metal stents. *Am J Gastroenterol* 2011;106:286-93.
9. Garcia-Alonso FJ, Sanchez-Ocana R, Peñas-Herrero I, et al. Cumulative risks of stent migration and gastrointestinal bleeding in patients with lumen-apposing metal stents. *Endoscopy* 2018;50: 386-95.
10. Rogalski P, Daniluk J, Baniukiewicz A, et al. Endoscopic management of gastrointestinal perforations, leaks and fistulas. *World J Gastroenterol* 2015;21:10542-52.

Henry Ford Hospital, Division of Gastroenterology, Detroit, Michigan.

If you would like to chat with an author of this article, you may contact Dr Jou at jjou1@hfhs.org.

Copyright © 2021 American Society for Gastrointestinal Endoscopy. Published by Elsevier Inc. This is an open access article under the CC BY-NC-ND license (<http://creativecommons.org/licenses/by-nc-nd/4.0/>).

<https://doi.org/10.1016/j.vgie.2020.09.010>