

Henry Ford Health

Henry Ford Health Scholarly Commons

Diagnostic Radiology Articles

Diagnostic Radiology

8-27-2022

A 75-year-old woman with left hand pain

Steven B. Soliman

Henry Ford Health, stevens@rad.hfh.edu

Follow this and additional works at: https://scholarlycommons.henryford.com/radiology_articles


Recommended Citation

Soliman SB. A 75-year-old woman with left hand pain. *Skeletal Radiol* 2022.

This Article is brought to you for free and open access by the Diagnostic Radiology at Henry Ford Health Scholarly Commons. It has been accepted for inclusion in Diagnostic Radiology Articles by an authorized administrator of Henry Ford Health Scholarly Commons.



A 75-year-old woman with left hand pain

Steven B. Soliman¹ 

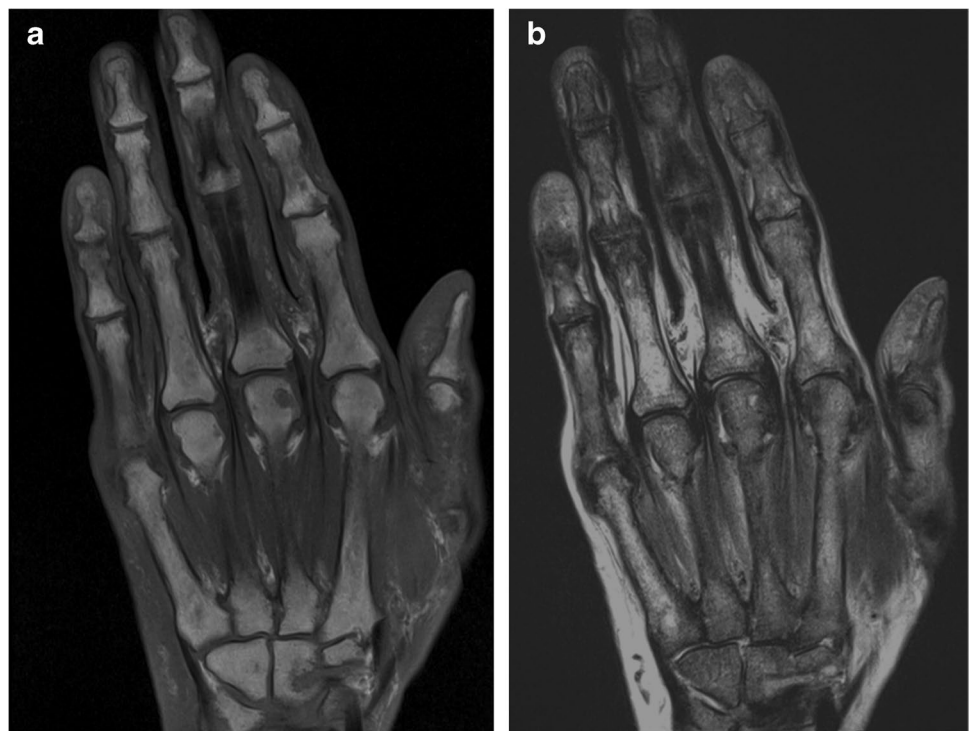Received: 26 July 2022 / Revised: 20 August 2022 / Accepted: 22 August 2022
© The Author(s), under exclusive licence to International Skeletal Society (ISS) 2022

History

A 75-year-old woman presented with a 4-week history of left hand pain and some swelling. The patient had a history of chronic kidney disease with a recent history of a small

bowel obstruction with intractable nausea and vomiting, and a decreased appetite. There was no history of trauma or any underlying inflammatory arthropathy (Figs. 1 and 2).

Fig. 1 Coronal MR images of the left hand. (a) Coronal T1W TSE and (b) coronal STIR



The diagnosis can be found at <https://doi.org/10.1007/s00256-022-04173-8>

✉ Steven B. Soliman
stevens@rad.hfh.edu

¹ Division of Musculoskeletal Radiology, Department of Radiology, Henry Ford Hospital, Detroit, MI, USA

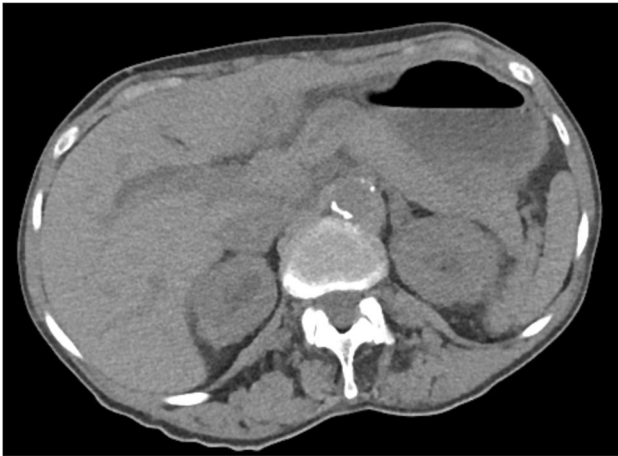

Fig. 2 Axial CT image of the upper abdomen

Declarations

All procedures performed in studies involving human participants were in accordance with the ethical standards of the institutional and/or national research committee and with the 1964 Helsinki declaration and its later amendments or comparable ethical standards. Informed consent was obtained from the subject described in this report. Institutional review board protocol review was exempt per our institutional review board policies for this type of manuscript and since these examinations were clinically indicated. Our study complied with the Health Insurance Portability and Accountability Act.

Conflict of interest The authors declare that they have no conflict of interest.

Publisher's note Springer Nature remains neutral with regard to jurisdictional claims in published maps and institutional affiliations.