

Henry Ford Health System

Henry Ford Health System Scholarly Commons

Orthopaedics Articles

Orthopaedics / Bone and Joint Center

10-1-2021

Supraspinatus-to-Glenoid Contact Occurs During Standardized Overhead Reaching Motion

Gaura Saini

Rebekah L. Lawrence

Justin L. Staker

Jonathan P. Braman

Paula M. Ludewig

Follow this and additional works at: https://scholarlycommons.henryford.com/orthopaedics_articles

Supraspinatus-to-Glenoid Contact Occurs During Standardized Overhead Reaching Motion

Gaura Saini,* DPT, Rebekah L. Lawrence,*[†] DPT, PhD, Justin L. Staker,*[‡] PT, PhD, Jonathan P. Braman,[§] MD, MHA, and Paula M. Ludewig,*^{¶||} PT, PhD

Investigation performed at the University of Minnesota, Minneapolis, Minnesota, USA

Background: Rotator cuff tears may result from repeated mechanical deformation of the cuff tendons, and internal impingement of the supraspinatus tendon against the glenoid is one such proposed mechanism of deformation.

Purpose: To (1) describe the changing proximity of the supraspinatus tendon to the glenoid during a simulated overhead reaching task and (2) determine the relationship between scapular morphology and this proximity. Additionally, the patterns of supraspinatus-to-glenoid proximity were compared with previously described patterns of supraspinatus-to-coracoacromial arch proximity.

Study Design: Descriptive laboratory study.

Methods: Shoulder models were created from magnetic resonance images of 20 participants. Standardized kinematics were imposed on the models to simulate functional reaching, and the minimum distances between the supraspinatus tendon and the glenoid and the supraspinatus footprint and the glenoid were calculated every 5° between 0° and 150° of humerothoracic elevation. The angle at which contact between the supraspinatus and the glenoid occurred was documented. Additionally, the relationship between glenoid morphology (version and inclination) and the contact angle was evaluated. Descriptive statistics were calculated for the minimum distances, and glenoid morphology was assessed using Pearson correlation coefficients and simple linear regressions.

Results: The minimum distances between the tendon and the glenoid and between the footprint and the glenoid decreased as elevation increased. Contact between the tendon and the glenoid occurred in all participant models at a mean elevation of 123° ± 10°. Contact between the footprint and the glenoid occurred in 13 of 20 models at a mean of 139° ± 10°. Less glenoid retroversion was associated with lower tendon-to-glenoid contact angles ($r = -0.76$; $R^2 = 0.58$; $P < .01$).

Conclusion: This study found that the supraspinatus tendon progressively approximated the glenoid during simulated overhead reaching. Additionally, all participant models eventually made contact with the glenoid by 150° of humerothoracic elevation, although anatomic factors influenced the precise angle at which contact occurred.

Clinical Relevance: Contact between the supraspinatus and the glenoid may occur frequently within the range of elevation required for overhead activities. Therefore, internal impingement may be a prevalent mechanism for rotator cuff deformation that could contribute to cuff pathology.

Keywords: internal impingement; shoulder impingement; shoulder kinematics; shoulder motion

Rotator cuff tears affect approximately 40% of individuals over the age^{14,25,40} of 60 years and are often associated with significant pain and functional decline.³⁴ There are many theorized contributors to rotator cuff pathology (eg, hypovascularity, diminished elastic properties, matrix composition, and tendon morphology).^{4,11,13,37,40} Repeated tendon deformation from nearby anatomic structures during shoulder motion is believed to be a common additional

contributory mechanism.^{28,39} However, specific causes, magnitudes, and locations of rotator cuff deformation are not well-understood, which limits our understanding of potential mechanisms for degenerative rotator cuff pathology.

Internal impingement of the rotator cuff against the glenoid is one potential mechanism of rotator cuff deformation and may occur more frequently than previously thought. Internal impingement was first identified in a position of abduction in combination with maximal external rotation.³⁹ However, there is increasing evidence that internal impingement may occur during glenohumeral

The Orthopaedic Journal of Sports Medicine, 9(10), 23259671211036908

DOI: 10.1177/23259671211036908

© The Author(s) 2021

This open-access article is published and distributed under the Creative Commons Attribution - NonCommercial - No Derivatives License (<https://creativecommons.org/licenses/by-nc-nd/4.0/>), which permits the noncommercial use, distribution, and reproduction of the article in any medium, provided the original author and source are credited. You may not alter, transform, or build upon this article without the permission of the Author(s). For article reuse guidelines, please visit SAGE's website at <http://www.sagepub.com/journals-permissions>.

elevation, even in the absence of maximal external rotation.^{7,17,21,30,31} Consequently, the shoulder pain commonly reported by patients above 90° of elevation—traditionally attributed to subacromial impingement¹⁰—may be the result of internal impingement of the supraspinatus on the glenoid. This theory is supported by recent findings that the supraspinatus has cleared the acromion in most people by 90° of humeral elevation.^{2,19}

Despite the increasing focus on internal impingement as a potential mechanism for rotator cuff pathology, few studies have investigated kinematic and anatomic factors that may affect the minimum distance between the supraspinatus tendon and the glenoid. A previous study⁷ of 9 asymptomatic participants evaluated the effect of active humerothoracic elevation on the supraspinatus-to-glenoid minimum distance. Those authors found the smallest supraspinatus-to-glenoid distance at the maximal humerothoracic elevation tested—approximately 100°. However, it remains unclear the extent to which tendon proximity to the glenoid changes throughout the full range of humeral elevation. In addition, individual anatomy—particularly variations in the glenoid shape and orientation—may have an effect on the proximity of the supraspinatus tendon to the glenoid.⁹

The purposes of this study were to (1) describe the changing proximity of the supraspinatus tendon to the glenoid during a simulated overhead reaching task and to (2) determine the extent to which scapular morphology affects this proximity. We hypothesized that the distance between the supraspinatus tendon and the glenoid would decrease as humerothoracic elevation increased and that scapular morphology would have no relationship with supraspinatus-to-glenoid proximity.

METHODS

Participants

Institutional review board approval was received for the study protocol, and participant enrollment occurred from 2013 to 2016. A total of 20 participants from 2 groups ($n = 10$ symptomatic; $n = 10$ asymptomatic) were recruited for this study. Asymptomatic participants were of interest, in addition to symptomatic participants, because of the high prevalence of asymptomatic tendinopathy and rotator cuff tears.¹

For the symptomatic group, participants were included if they reported current pain or a history of pain in the anterolateral region of the studied shoulder; participants were excluded if their shoulder pain began after a traumatic injury, was reproduced during a cervical spine screen, or was associated with a loss of shoulder range of motion >25% compared with the contralateral side in at least 2 of 3 motions (flexion-extension, abduction-adduction, or internal-external rotation).³⁵ Asymptomatic participants were included if they reported no history of shoulder pain. Participants were excluded from either group if they reported a history of shoulder fracture, dislocation, inflammatory joint disease, or adhesive capsulitis.

Although group comparisons were not the primary objective of this study, characteristics, minimum supraspinatus-to-glenoid distances, and glenoid morphology between groups were analyzed to ensure there was no confounding effect of group. Characteristics information is available in Table 1. There were no statistically significant differences in characteristics between groups.

Data Processing

The methods largely followed those of previous work described elsewhere.¹⁹ Briefly, magnetic resonance (MR) images were obtained for all participants using a 3-T Siemens Magnetom SKYRA system (Siemens Healthcare) and a specialized sequence to visualize tendon margins. These images were subsequently manually segmented to create 3-dimensional (3D) models of the humerus, the scapula, and the supraspinatus tendon (Mimics software; Materialise). While creating the supraspinatus tendon models, the delineation between the supraspinatus and the infraspinatus was carefully identified and often resulted in the infraspinatus inserting onto the superior facet of the greater tubercle in accordance with its insertion described by Mochizuki et al.²⁷ (Figure 1). For the purposes of this study, 2 regions of interest were defined on the supraspinatus tendon. First, the supraspinatus footprint was defined as the enthesis portion of the supraspinatus tendon inserting into the humerus (Figure 1A). Second, the supraspinatus tendon region was defined as the supraspinatus footprint plus the 1-cm portion of the supraspinatus tendon immediately medial to the footprint (Figure 1, A and B). This portion of the supraspinatus tendon corresponds to the region where most tears are thought to initiate.^{8,22}

^{||}Address correspondence to Paula M. Ludewig, PT, PhD, MMC 388, 420 Delaware St, SE, Minneapolis, MN 55455, USA (email: ludew001@umn.edu) (Twitter: @MNRRehabBiomech)

^{*}Division of Rehabilitation Science, Department of Rehabilitation Medicine, University of Minnesota, Minneapolis, Minnesota, USA.

[†]Department of Orthopaedic Surgery, Henry Ford Health System, Detroit, Michigan, USA.

[‡]Division of Physical Therapy, Department of Rehabilitation Medicine, University of Minnesota, Minneapolis, Minnesota, USA.

[§]Department of Orthopedic Surgery, University of Minnesota, Minneapolis, Minnesota, USA.

Final revision submitted April 5, 2021; accepted May 13, 2021.

One or more of the authors has declared the following potential conflict of interest or source of funding: Data collection and analysis for this project was supported by the Eunice Kennedy Shriver National Institute of Child Health and Human Development (award number R03-HD070871 to P.M.L.). The content is solely the responsibility of the authors and does not necessarily represent the official views of the Eunice Kennedy Shriver National Institute of Child Health and Human Development or the National Institutes of Health. Preparation and editing of this manuscript was supported by a predoctoral training grant (T32-AR050938) through the National Institute of Arthritis and Musculoskeletal and Skin Diseases (T32-AR050938 to G.S.). J.P.B. has received consulting fees from Zimmer Biomet. AOSSM checks author disclosures against the Open Payments Database (OPD). AOSSM has not conducted an independent investigation on the OPD and disclaims any liability or responsibility relating thereto.

Ethical approval for this study was obtained from the University of Minnesota (protocol No. 0604M84447).

TABLE 1
Participant Characteristics^a

	Asymptomatic (n = 10)	Symptomatic (n = 10)	P Value (95% CI)
Age, y	38.5 ± 12.8	43 ± 11.8	.42 (−16.08 to 7.08) ^b
Height, cm	172.8 ± 8.8	169.7 ± 9.9	.46 (−0.06 to 0.12) ^b
Weight, kg	75.9 ± 14.2	77.1 ± 16.5	.90 (−15.07 to 13.35) ^b
BMI, kg/m ²	25.5 ± 4.3	26.7 ± 5.3	.59 (−5.72 to 3.35) ^b
Sex (% male)	5 (50)	4 (40)	≥.99 (0.08 to 5.36) ^c
Side tested (% dominant)	8 (80)	10 (100)	.47 (0.19 to ∞) ^c

^aData are presented as mean ± SD or n (%). BMI, body mass index.

^bIndependent 2-sample *t* test.

^cFisher exact test.

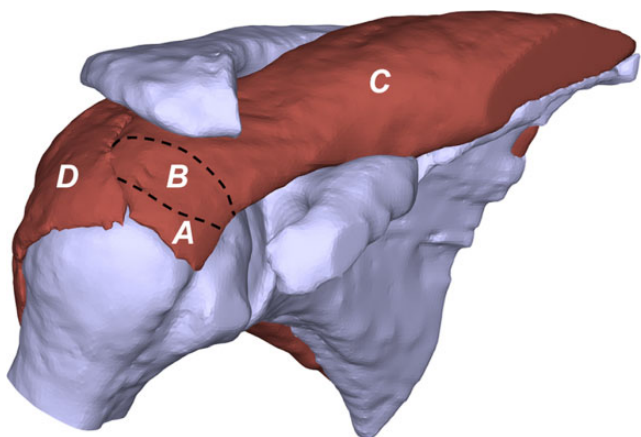


Figure 1. Supraspinatus regions of interest. (A) Supraspinatus footprint: the portion of the supraspinatus tendon inserting into the humerus. (A and B together) Supraspinatus tendon region: the footprint and the portion of the supraspinatus tendon that was 1 cm medial to the footprint. (C) The supraspinatus muscle and (D) the infraspinatus tendon and muscle. Note that the infraspinatus insertion was often found to overlap with the supraspinatus to insert onto superior facet of the greater tuberosity, which is consistent with the description by Mochizuki et al.²⁷

Although the footprint was also contained within the tendon region, the footprint in isolation was still of interest to facilitate comparison of findings with previous work that quantified minimum distances to only the bony supraspinatus insertion on the humerus.⁷

Each participant's 3D models were rotated as rigid bodies using standardized angular kinematics that simulated a functional reaching task. The standardized kinematics were derived from a previous study in which asymptomatic participants were asked to raise their arm as if reaching for an object on a high shelf with no attempt to control the plane of motion or height of reaching.⁵ The mean plane of motion across participants varied throughout the simulated motion, ranging from approximately 7° to 23° anterior to the scapular plane.⁵ That study extracted the mean humerothoracic, scapulothoracic, and glenohumeral joint angles across all participants. For the purpose of this study,

the standardized kinematics were defined as the mean glenohumeral angular kinematics at each 5° increment of humerothoracic elevation between 0° to 150° from the previous study.⁵ Throughout the simulated reaching task, the humeral head remained centered on the glenoid, such that no translations occurred. Additionally, a standardized humeral retroversion^{19,24} was simulated because the humeral epicondyles could not be imaged because of restrictions of the MR scanner's field of view. The minimum distance of the supraspinatus footprint and tendon region relative to the glenoid was the specific measure of proximity.

The use of standardized kinematics allowed us to directly assess the extent to which the humerothoracic elevation angle and anatomic morphology affected the proximity of the supraspinatus tendon and the glenoid. For example, within-participant changes in minimum distances across the range of motion can be directly attributed to the humerothoracic elevation angle as all other kinematics were held constant. Furthermore, between-participant differences in minimum distances at the same humerothoracic elevation angle can be directly attributed to anatomic differences.

At each increment of simulated humerothoracic elevation, minimum distances were calculated using a custom MATLAB code (MathWorks) between the surfaces of the glenoid and (1) the supraspinatus footprint and (2) the supraspinatus tendon region.^{19,20} From these calculations, 2 primary outcome measures were calculated for both the supraspinatus tendon region and the footprint. First, the minimum distance between the glenoid and the supraspinatus tendon region or the footprint was calculated as the smallest distance between structures for each humerothoracic elevation angle. Second, if the supraspinatus tendon region or the footprint came into contact with the glenoid during the simulation (ie, minimum distance of 0 mm, beyond which the tendon model would physically overlap with the glenoid model), the humerothoracic angle at which contact occurred was documented (Figure 2). The patterns of supraspinatus-to-glenoid minimum distances were then compared with previously described patterns of supraspinatus-to-coracoacromial arch minimum distances.¹⁹

Also, 3D glenoid morphology (glenoid version and inclination) was calculated by relating the orientation of the glenoid axes to the scapular axes. The axes of the glenoid

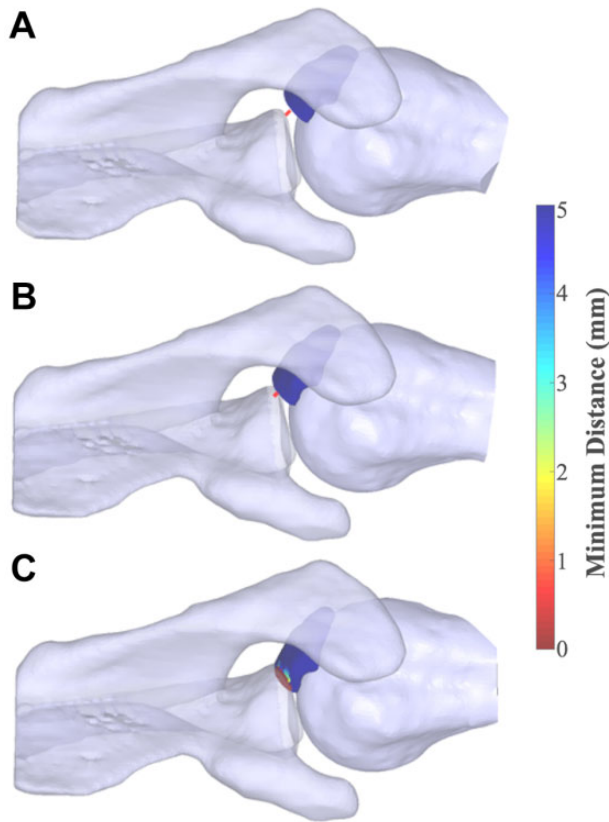


Figure 2. The minimum distance between the supraspinatus tendon region and the glenoid at 3 humerothoracic elevation positions in a representative participant (superior view). Red-color mapping on the tendon indicates contact. The scapula is semitransparent so as to allow for visualization of the supraspinatus tendon. (A) At 110° of simulated humerothoracic elevation (glenohumeral position of 70° elevation, humeral plane of elevation 17° anterior to the scapular plane, and 66° humeral external rotation), the supraspinatus tendon region is 6.1 mm from the glenoid. (B) At 120° humeral elevation (glenohumeral position of 78° elevation, humeral plane of elevation 14° anterior to the scapular plane, and 65° humeral external rotation), the supraspinatus tendon region is 3.7 mm from the glenoid. (C) At 130° humeral elevation (glenohumeral position of 85° elevation, humeral plane of elevation 9° anterior to the scapular plane, and 64° humeral external rotation), the supraspinatus tendon region is contacting the glenoid (red color).

were determined using a principal-components analysis of points along the glenoid rim. The analysis resulted in orthogonal axes in which the first principal axis was predominantly directed superiorly-inferiorly (G_y axis) (Figure 3), the second principal axis was predominantly directed anteriorly-posteriorly (G_x axis), and the third principal axis was predominantly directed medially-laterally, perpendicular to the face of the glenoid (G_z axis). A scapular reference frame was defined using the following

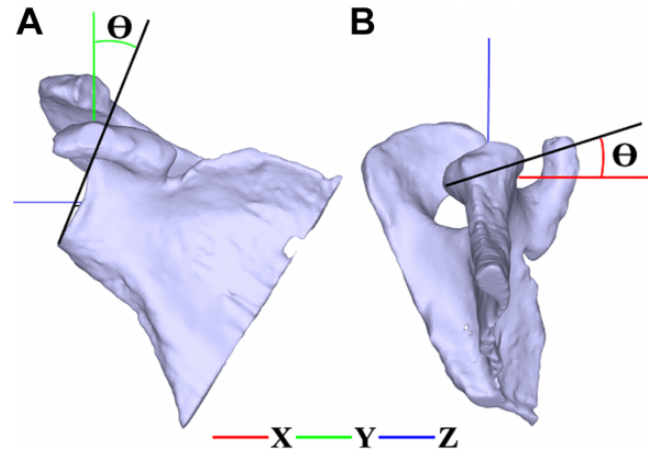


Figure 3. The glenoid and scapular coordinate systems used to calculate (A) glenoid inclination (θ) and (B) glenoid version (θ). The scapular reference frame is represented by the red, green, and blue lines and is defined by the root of the scapular spine, the inferior angle, and the glenoid center landmarks. The scapular superior-inferior axis was perpendicular to the line from the root of the scapular spine to the glenoid center (green), and the scapular anterior-posterior axis was perpendicular to the plane of the scapula (red). The origin of the scapular reference frame is located at the glenoid center. The glenoid reference frame axes are represented by black lines. Glenoid inclination was defined as the angle between the scapular superior-inferior axis and the glenoid superior-inferior axis after projecting the glenoid axes on the scapular plane. This definition is consistent with other biomechanical research and results in an inclination value that is approximately complementary to the β angle.⁶ Glenoid version was defined as the angle between the scapular anterior-posterior axis and the glenoid anterior-posterior axis after projecting the glenoid axes on the transverse scapular plane.

landmarks: the root of the scapular spine, the inferior angle, and the glenoid center. The first scapular axis (S_z axis) was directed laterally from the root of the spine to the glenoid center, the second axis (S_x axis) was directed anteriorly perpendicular to the plane of the scapula defined by the 3 landmarks, and the third axis (S_y axis) was perpendicular to the first 2 and directed superiorly. Glenoid inclination was calculated as the angle between the scapular superior-inferior axis (perpendicular to the line from the root of the scapular spine to the glenoid center) and the glenoid superior-inferior axis after projecting the glenoid axes onto the scapular coronal plane (Figure 3A). This technique results in an inclination value that is approximately complementary to the β angle and is consistent with other biomechanical research.⁶ The glenoid version was calculated as the angle between the scapular anterior-posterior axis (perpendicular to the plane of the scapula) and the glenoid anterior-posterior axis after projecting the glenoid axes onto the scapular transverse plane (Figure 3B). Using these calculations, positive values indicated glenoid inclination and anteversion, respectively.

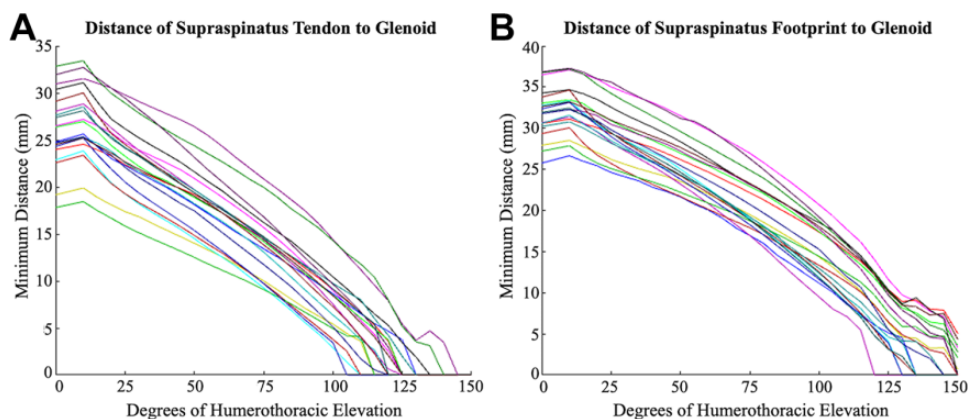


Figure 4. Models for each participant: the minimum distance between the glenoid and (A) the supraspinatus tendon region and (B) the footprint across the simulated functional reaching task.

Statistical Analysis

Group differences were not expected because of the use of standardized kinematics in the overhead reaching task simulation. However, groups were compared statistically to ensure that any unexpected group differences because of anatomic differences did not confound the results. Demographic data were compared between groups using 2-sample *t* tests or Fisher exact tests, as appropriate. Descriptive statistics were calculated for the minimum distances between the glenoid and the supraspinatus tendon region and the glenoid and the footprint across the humerothoracic elevation angle. Before the statistical analysis, all variables were assessed for normality within each group using the skewness and kurtosis coefficients. For the tendon region to the glenoid contact angle, data were found to be non-normal, and the subsequent transformation was unsuccessful. Thus, the tendon region-to-glenoid contact angles were compared between groups using a nonparametric Mann-Whitney test. For the footprint-to-glenoid contact angle, several models did not make contact within the 150° simulation, which precluded group comparisons. Instead, the footprint-to-glenoid contact angle data are provided descriptively. Finally, morphology data were not normally distributed, and transformation of the data was unsuccessful. Thus, nonparametric Mann-Whitney tests were used to compare groups. The extent to which the tendon region-to-glenoid contact angle was associated with glenoid morphology (inclination and version) was assessed using Pearson correlation coefficients and simple linear regressions. The level of significance for all analyses was *P* < .05. All statistics were performed using R 3.5.1 (R Foundation for Statistical Computing).

RESULTS

Overall, the minimum distance between the glenoid and the supraspinatus tendon region decreased as humerothoracic elevation increased (Figure 4A). At 90° humerothoracic elevation, the mean tendon region-to-glenoid minimum

TABLE 2
Group Comparisons^a

	Asymptomatic	Symptomatic	<i>P</i> Value (95% CI) ^b
Tendon contact elevation angle, deg	122 ± 11	125 ± 9	.67 (−15 to 5)
Glenoid version, deg	−12.1 ± 3.4	−14.4 ± 4	.14 (−1.91 to 6.25)
Glenoid inclination, deg	11.6 ± 4.5	13.1 ± 4.3	.28 (−6 to 1.60)

^aData are reported as mean ± SD.
^bNonparametric Mann-Whitney test.

distance across participants’ models was 10.4 ± 3.3 mm, which reduced to 2.3 ± 2.7 mm at 120° and 0 ± 0 mm at 150°. The minimum distance between the glenoid and the footprint, like the tendon region, decreased as humerothoracic elevation increased (Figure 4B). The mean minimum distance between the glenoid and the supraspinatus footprint was 17.4 ± 3.2 mm at 90°, 8.7 ± 3.6 mm at 120°, and 1.1 ± 1.7 mm at 150°.

Contact between the supraspinatus tendon region and the glenoid eventually occurred in all participant models, and there were no significant differences in the contact angle between groups (*P* = .67; 95% CI, −15 to 5) (Table 2). Initial tendon region contact occurred at a mean humerothoracic elevation angle of 123° ± 10° but ranged from 105° to 145°. Contact between the supraspinatus footprint and the glenoid occurred in 13 out of 20 participant models (65%). Of those that made contact, initial contact occurred at a mean humerothoracic elevation angle of 139° ± 10°.

There were no group differences in glenoid morphology (glenoid inclination: *P* = .28; 95% CI, −6.00 to 1.60; glenoid version: *P* = .14; 95% CI, −1.91 to 6.25) (Table 2). The strongest association between glenoid morphology and the supraspinatus tendon region-to-glenoid contact angle was found for glenoid version (*r* = −0.76; *R*² = 0.58; *P* < .01) (Figure 5). The negative correlation indicates that

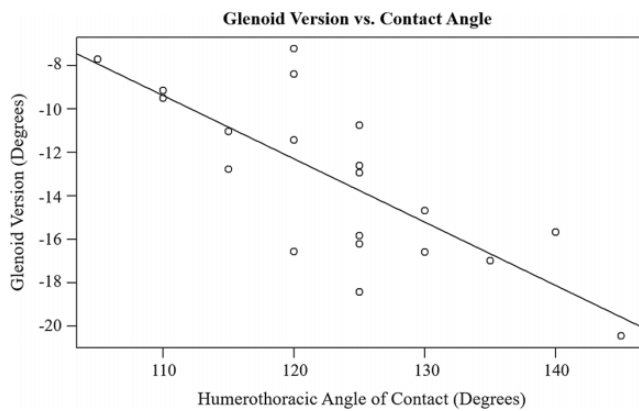


Figure 5. Relationship between the glenoid version and the degree of humerothoracic elevation at which a contact between the supraspinatus tendon and the glenoid first occurs. The negative version represents retroversion ($r = -0.76$; $R^2 = 0.58$; $P < .01$).

participant models with less glenoid retroversion tended to experience contact at lower angles of humerothoracic elevation. The glenoid inclination was weakly but insignificantly ($r = 0.18$; $R^2 = 0.03$; $P = .46$) associated with the contact angle. Based on a post hoc analysis of this study's sample size, the statistical power available for these correlations was the ability to detect $r \geq 0.60$ as significant ($\alpha = .05$), with a power of 80%.

DISCUSSION

The primary purpose of this study was to investigate the effect of humeral elevation on measures of proximity as a proxy for internal impingement of the supraspinatus tendon against the glenoid. Our results show that as the humeral elevation angle increased, the minimum distance between the glenoid and the supraspinatus tendon region decreased until contact occurred at a mean of $123^\circ \pm 10^\circ$ of elevation, ranging from 105° to 145° (Figure 4A). As the humeral elevation increased, the minimum distance between the glenoid and the supraspinatus footprint decreased as well. With regard to the tendon region, contact with the glenoid eventually occurred in all participant models. In this rigid body modeling, once contact was made between the supraspinatus and the glenoid, further elevation resulted in the supraspinatus and the glenoid occupying the same physical space, which cannot occur physiologically. Rather, the supraspinatus must deform around the glenoid. The results also demonstrated that a more anteriorly oriented glenoid (ie, less glenoid retroversion) was associated with earlier contact between the glenoid and the supraspinatus tendon ($r = -0.76$; $R^2 = 0.58$; $P < .01$), suggesting that scapular morphology likely affects proximity measurements.

Similar to the current study, a study by Coats-Thomas et al⁷ investigated the effect of humerothoracic elevation on the internal impingement "risk" in 9 asymptomatic participants. Risk was determined by a bone-to-bone minimum

distance between the supraspinatus tendon footprint and the glenoid using bilateral MR-based 3D models and participant-specific scapular plane abduction kinematics. Although the authors found that the minimum distance between the footprint and the glenoid decreased as the humeral elevation angle increased, in agreement with the findings of the current study, they also found smaller minimum distances. For example, at 100° of humerothoracic elevation, Coats-Thomas et al found a mean minimum distance of approximately 10 mm between the supraspinatus bony footprint and the glenoid, while the current study found a mean minimum distance of 14.9 mm between the supraspinatus tendon footprint and the glenoid. The bone-to-bone minimum distance in the current study would have been even larger than 14.9 mm, as it would have included the space occupied by the footprint portion of the tendon, generally 3- to 6-mm thick in this region.¹² Additionally, Coats-Thomas et al found that the minimum distance between the bony insertion and the glenoid was never less than the high-risk threshold of 4 mm (based on expected soft tissue thickness). However, the current study found minimum distances decreased below 4 mm during elevations beyond 100° , even to the point of contact in 13 out of 20 models.

Methodological factors likely contributed to the differences in results between Coats-Thomas et al⁷ and the current study. First, Coats-Thomas et al evaluated minimum distances from a small sample of participant-specific kinematics collected during weighted scapular plane abduction. In comparison, the current study used standardized kinematics determined by the mean glenohumeral rotations from 12 participants during an overhead reaching task.⁵ The plane of humeral elevation may influence the supraspinatus tendon's proximity to surrounding structures and could partially explain the differences in findings.²⁰ Further, the humeral head remained centered in the glenoid throughout motion in the current study. Participant-specific changes in humeral rotation or translation may have altered the minimum distances found in this study. Last and most important, the participants in the Coats-Thomas et al study did not perform humerothoracic elevation above a mean of 100° , whereas the current study investigated motion through 150° . Had they continued to collect minimum distances through the full range of humerothoracic elevation, Coats-Thomas et al may have also found evidence of contact between the supraspinatus footprint and the glenoid.

While the analysis of the minimum distance between the footprint and the glenoid facilitates comparison with previous studies, it does not represent internal impingement of the deformable aspect of the tendon. Importantly, our analysis of the supraspinatus tendon region found that contact with the glenoid occurred at a mean elevation angle of 123° and contact eventually occurred in every model. This contact was consistently occurring, even with standardized kinematics, including the humeral head fixed at the center of the glenoid (Figure 4). Theoretically, if a participant's humeral head were to translate inferiorly even a small amount during overhead reaching, the undersurface of the supraspinatus tendon may make

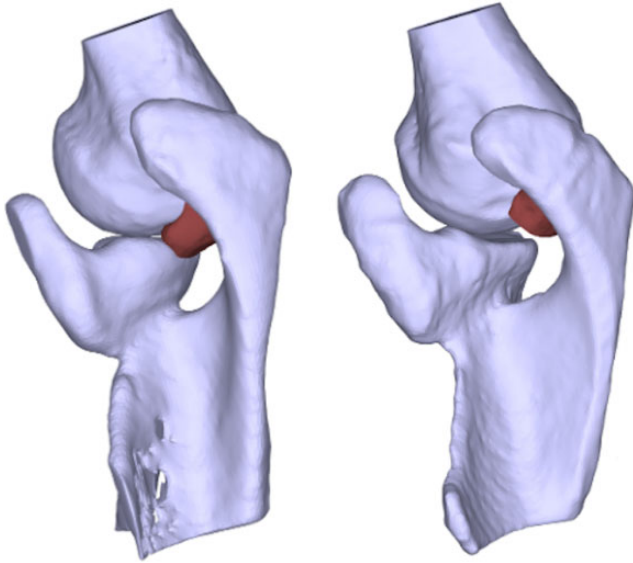


Figure 6. A comparison of the impact of the glenoid version from a superior view. The glenoid on the left has -9.5° of version, while the glenoid on the right has -20.5° of version. The glenoid on the right is more retroverted, and the superior border of the glenoid may remain clear of the supraspinatus tendon (red) into higher ranges of elevation compared with a less retroverted glenoid. The effect of glenoid retroversion on the contact angle is most relevant during elevation combined with humeral external rotation, as was simulated in this study.

contact with the glenoid at a lower elevation angle. Further, scapulothoracic upward rotation may also affect the tendon to the glenoid contact angle. For example, at a given angle of humerothoracic elevation, if the scapula were to be in a position of less upward rotation relative to humeral elevation, the superior rim of the glenoid would theoretically be in a position more likely to make contact with the supraspinatus tendon. Alternatively, increased upward rotation relative to humeral elevation could be protective in maximizing the humerothoracic range of motion before internal impingement or tendon-to-glenoid contact would occur. However, these theories require more research to understand how alterations in scapular motion or humeral translation affect mechanisms of internal impingement *in vivo*.

Substantial variability in the minimum distance was observed between participants at all angles of elevation (Figure 4). Because the research protocol imposed standardized kinematics and humeral retroversion across participants, between-participant variability in minimum distances can only be because of anatomic differences. One such anatomic feature that varies across participants is the amount of glenoid version. The results of this study suggest that 58% of the variability in the contact angle between participants may be explained by glenoid version (Figure 5). Specifically, as the glenoid becomes less retroverted, the posterior-superior rim of the glenoid tends to be closer to the path of the supraspinatus tendon, allowing contact to

occur at lower ranges of humeral elevation compared with a more retroverted glenoid (Figure 6). This is particularly relevant for humeral elevation motions during which the humerus is also externally rotating, bringing the insertion of the supraspinatus closer to the posterior-superior glenoid rim.

Given that the supraspinatus tendon region made contact with the glenoid in all participant models during the elevation simulation, it is possible that, regardless of anatomy, contact will eventually occur if an individual reaches high enough overhead. Walch et al³⁹ proposed that contact between the supraspinatus tendon and the glenoid is physiological and becomes pathological with repetitive exposure. The mechanism for pathology is likely more complex than contact alone; the frequency of contact and the inherent and biologic resilience of the tissue need to be considered also. Our findings indicate that contact may occur during overhead reaching beyond 120° , even without extremes of external rotation typically considered. Overhead reaching is a common motion in typical daily activities of the general population.²⁹ Therefore, internal impingement from contact between the supraspinatus and the glenoid may be occurring much more commonly than previously thought.

In addition to describing the minimum distances and prevalence of contact between the supraspinatus tendon and the glenoid during a simulated overhead reaching task, a secondary purpose of this study was to descriptively compare these results with those from a previous investigation of supraspinatus tendon proximities to the coracoacromial arch using a similar methodology.¹⁹ As expected, subacromial and internal supraspinatus contact—with the coracoacromial arch and glenoid, respectively—occur in distinct ranges of humeral elevation within the same functional reach simulation (Figure 7). Specifically, the supraspinatus tendon was closest to the coracoacromial arch between 0° to 60° humerothoracic elevation, whereas it approached the glenoid above 100° humerothoracic elevation. However, the prevalence of contact yielded the most surprising comparison between studies. Contact between the supraspinatus tendon and the coracoacromial arch occurred in only 10 of 20 models, whereas the current study found that contact between the supraspinatus tendon and the glenoid eventually occurred in all 20 models. Taken together, these findings suggest that deformation of the supraspinatus tendon against the glenoid may occur more frequently and at higher angles of elevation compared with deformation of the supraspinatus tendon beneath the coracoacromial arch (Figure 7). Therefore, the findings of this study suggest that glenoid or internal impingement may be a more prevalent mechanism for rotator cuff deformation, deserving more research attention. Further, these findings may spur further discussion into other anatomic factors that influence rotator cuff compression or deformation with shoulder motion.

We recommend that clinicians bear the results of this study in mind when educating patients about pain alleviation and the risks of further injury. This study adds to the body of literature, indicating that overhead reaching may increase the risk of shoulder pain and injury.^{3,26,32,33,36,38}

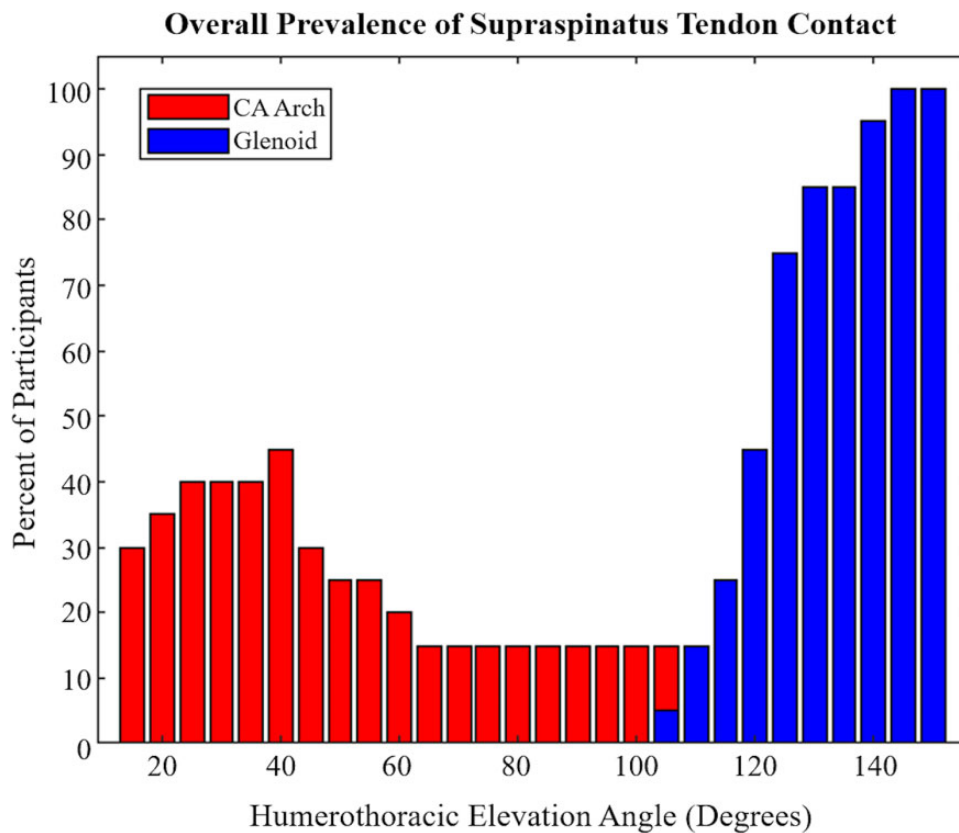


Figure 7. Prevalence (percentage of participants) of contact between the supraspinatus tendon and the coracoacromial (CA) arch and the glenoid across humerothoracic elevation angles during simulated overhead reaching in 20 participants. Contact between the supraspinatus and the CA arch was defined as a volume of intersection between the tendon and the CA arch $>0 \text{ mm}^3$ (Lawrence et al¹⁹). Contact between the supraspinatus and the glenoid was defined as a minimum distance between the tendon and the glenoid of $<0 \text{ mm}$.

Patients who perform repetitive or prolonged overhead activities should be informed of the risks thereof and should be taught mitigation strategies. Clinicians should also recognize that the findings of this study imply that commonly used clinical testing (eg, Neer impingement sign) are not measuring subacromial impingement as originally described. If a patient reported pain during the test with one's shoulder at, for example, 110° of shoulder elevation, the test would be considered positive and the clinician might suspect that the supraspinatus tendon was being compressed by the acromion. However, the data from this study suggest that the patient in this scenario may actually be experiencing supraspinatus compression or deformation from the glenoid (internal impingement), not the acromion. This should be kept in mind when determining clinical interventions, including surgical planning.

Limitations

This study had several limitations. First, the models were created from MR images taken in a supine position in which the supraspinatus muscle was relaxed, while a functional

reaching motion would occur in an upright position with a contracting supraspinatus. Muscle contraction increases muscle thickness during arm elevation¹⁵ but theoretically should not substantially alter tendon thickness. Studies have found that the portion of the supraspinatus included in this study is tendinous, not muscular¹⁶; therefore, we do not expect that muscle contraction would have substantially altered our results. However, further research is needed to understand how muscle contraction changes rotator cuff musculotendinous thickness during overhead reaching.

Second, the anatomic models in this study used a standardized amount of humeral retroversion, as the humeral epicondyles were not imaged because of the limited field of view of the MR scanner.¹⁹ While this meant the initial alignment of the models was not participant-specific, the standardized humeral retroversion also eliminated a potential source of variance by allowing us to directly assess the effects of humerothoracic elevation on minimum distance without confounding effects from between-participant differences in humeral retroversion. Nevertheless, the degree of retroversion may affect the minimum distance between

the supraspinatus and the glenoid, and more research is needed to fully understand the influence of these anatomic variations.

Third, the study design fixed the humeral head at the center of the glenoid throughout the reaching movement, although other studies have shown that the humeral head does not necessarily stay centered during movement.^{2,18,23} Like retroversion, we standardized humeral translation in this study to eliminate confounding our analysis of the effects of humeral elevation on minimum distance of the supraspinatus tendon to the glenoid. Superior translation may increase minimum distances to the glenoid and reduce the risk of tendon contact and deformation, while inferior translation may decrease minimum distances and increase the risk of tendon contact with the glenoid.

Fourth, the quality of the supraspinatus tendon and muscle tissue was not directly evaluated in this study. However, a board-certified orthopaedic surgeon (J.P.B.) reviewed all MR images, and no full-thickness rotator cuff tears were identified. Differences in tissue quality may influence individual kinematics, but as standardized kinematics were applied to all participant models in this study, we do not believe this limitation substantially affects the results.

Finally, the supraspinatus tendon was modeled as a rigid body in this study. As such, the modeled tendons could not deform or move away from the humeral head as they might in vivo. Future research should employ more complex computational models, such as finite element models, to assess tendon deformation during arm motion. This limitation does not affect our results of the proximity between the glenoid and the supraspinatus footprint, as this aspect of the tendon inserts directly into the humerus and moves with the humerus. Importantly, 65% of participant simulations in this study demonstrated contact between the footprint and the glenoid, although the mean humerothoracic elevation angle of the initial footprint contact (139°) was higher than that of the initial tendon contact. Thus, these findings still present a clear risk of internal impingement at high ranges of overhead reaching range of motion.

Despite these limitations, our study provides a direct analysis of the effect of humeral elevation on supraspinatus tendon proximity to the glenoid. Because kinematics were standardized across participants, variability in minimum distances can be attributed to anatomic differences. Therefore, we can begin to identify motion and anatomic factors that result in repeated tendon deformation during motion, which may subsequently lead to tendon degeneration. Future research is needed to determine what bony geometry most influences tendon deformation and directly assess tendon stresses and strains during arm motion. Additional longitudinal research is needed to determine if tendon deformation increases the risk of shoulder pain. Finally, future studies should investigate which participant-specific movement patterns affect tendon deformation to inform conservative rehabilitation treatment.

CONCLUSION

The supraspinatus tendon progressively approximated the glenoid throughout humerothoracic elevation and eventually made contact with the glenoid by 150° in all overhead reaching simulations in this study. Overall, the findings of this study suggest that contact between the supraspinatus and the glenoid may occur frequently within the range of elevation required for functional overhead activities.

REFERENCES

1. Barreto RPG, Braman JP, Ludewig PM, Ribeiro LP, Camargo PR. Bilateral magnetic resonance imaging findings in individuals with unilateral shoulder pain. *J Shoulder Elbow Surg.* 2019;28(9):1699-1706.
2. Bey MJ, Brock SK, Beierwaltes WN, Zuel R, Kolowich PA, Lock TR. In vivo measurement of subacromial space width during shoulder elevation: technique and preliminary results in patients following unilateral rotator cuff repair. *Clin Biomech (Bristol, Avon).* 2007;22(7):767-773.
3. Björkstén MG, Boquist B, Talbäck M, Edling C. Reported neck and shoulder problems in female industrial workers: the importance of factors at work and at home. *Int J Ind Ergon.* 2001;27(3):159-170.
4. Blevins FT, Djurasovic M, Flatow EL, Vogel KG. Biology of the rotator cuff tendon. *Orthop Clin North Am.* 1997;28(1):1-16.
5. Braman JP, Engel SC, LaPrade RF, Ludewig PM. In vivo assessment of scapulohumeral rhythm during unconstrained overhead reaching in asymptomatic subjects. *J Shoulder Elbow Surg.* 2009;18(6):960-967.
6. Chalmers PN, Beck L, Granger E, Henninger H, Tashjian RZ. Superior glenoid inclination and rotator cuff tears. *J Shoulder Elbow Surg.* 2018;27(8):1444-1450.
7. Coats-Thomas MS, Massimini DF, Warner JJP, Seitz AL. In vivo evaluation of subacromial and internal impingement risk in asymptomatic individuals. *Am J Phys Med Rehabil.* 2018;97(9):659-665.
8. Codman EA. *The Shoulder.* Thomas Todd; 1934.
9. Drakos MC, Barker JU, Osbahr DC, et al. Effective glenoid version in professional baseball players. *Am J Orthop (Belle Mead NJ).* 2010;39(7):340-344.
10. Harrison AK, Flatow EL. Subacromial impingement syndrome. *J Am Acad Orthop Surg.* 2011;19(11):701-708.
11. Hashimoto T, Nobuhara K, Hamada T. Pathologic evidence of degeneration as a primary cause of rotator cuff tear. *Clin Orthop Relat Res.* 2003;415:111-120.
12. Karthikeyan S, Rai SB, Parsons H, Drew S, Smith CD, Griffin DR. Ultrasound dimensions of the rotator cuff in young healthy adults. *J Shoulder Elbow Surg.* 2014;23(8):1107-1112.
13. Katzer A, Wening JV, Becker-Männich HU, Lorke DE, Jungbluth KH. [Rotator cuff rupture. Vascular supply and collagen fiber processes as pathogenetic factors]. *Unfallchirurgie.* 1997;23(2):52-59.
14. Kim HM, Dahiya N, Teefey SA, et al. Location and initiation of degenerative rotator cuff tears: an analysis of three hundred and sixty shoulders. *J Bone Joint Surg Am.* 2010;92(5):1088-1096.
15. Kim S, Bleakney R, Boynton E, et al. Investigation of the static and dynamic musculotendinous architecture of supraspinatus. *Clin Anat.* 2010;23(1):48-55.
16. Kim SY, Boynton EL, Ravichandiran K, Fung LY, Bleakney R, Agur AM. Three-dimensional study of the musculotendinous architecture of supraspinatus and its functional correlations. *Clin Anat.* 2007;20(6):648-655.
17. Kim TK, McFarland EG. Internal impingement of the shoulder in flexion. *Clin Orthop Relat Res.* 2004;421:112-119.
18. Lawrence RL, Braman JP, Staker JL, LaPrade RF, Ludewig PM. Comparison of 3-dimensional shoulder complex kinematics in individuals with and without shoulder pain, part 2: glenohumeral joint. *J Orthop Sports Phys Ther.* 2014;44(9):646-655.

19. Lawrence RL, Schlangen DM, Schneider KA, et al. Effect of glenohumeral elevation on subacromial supraspinatus compression risk during simulated reaching. *J Orthop Res*. 2017;35(10):2329-2337.
20. Lawrence RL, Sessions WC, Jensen MC, et al. The effect of glenohumeral plane of elevation on supraspinatus subacromial proximity. *J Biomech*. 2018;79:147-154.
21. Leschinger T, Wallraff C, Muller D, Hackenbroch M, Bovenschulte H, Siewe J. Internal impingement of the shoulder: a risk of false positive test outcomes in external impingement tests? *Biomed Res Int*. 2017;2017:2941238.
22. Ling SC, Chen CF, Wan RX. A study on the vascular supply of the supraspinatus tendon. *Surg Radiol Anat*. 1990;12(3):161-165.
23. Ludewig PM, Cook TM. Translations of the humerus in persons with shoulder impingement symptoms. *J Orthop Sports Phys Ther*. 2002;32(6):248-259.
24. Massimini DF, Warner JJ, Li G. Glenohumeral joint cartilage contact in the healthy adult during scapular plane elevation depression with external humeral rotation. *J Biomech*. 2014;47(12):3100-3106.
25. Milgrom C, Schaffler M, Gilbert S, van Holsbeeck M. Rotator-cuff changes in asymptomatic adults. The effect of age, hand dominance and gender. *J Bone Joint Surg Br*. 1995;77(2):296-298.
26. Miranda H, Punnett L, Viikari-Juntura E, Heliövaara M, Knekt P. Physical work and chronic shoulder disorder. Results of a prospective population-based study. *Ann Rheum Dis*. 2008;67(2):218-223.
27. Mochizuki T, Sugaya H, Uomizu M, et al. Humeral insertion of the supraspinatus and infraspinatus. New anatomical findings regarding the footprint of the rotator cuff. *J Bone Joint Surg Am*. 2008;90(5):962-969.
28. Neer CS II. Anterior acromioplasty for the chronic impingement syndrome in the shoulder. *J Bone Joint Surg Am*. 1972;54(1):41-50.
29. Oosterwijk AM, Nieuwenhuis MK, van der Schans CP, Mouton LJ. Shoulder and elbow range of motion for the performance of activities of daily living: a systematic review. *Physiother Theory Pract*. 2018;34(7):505-528.
30. Pappas GP, Blemker SS, Beaulieu CF, McAdams TR, Whalen ST, Gold GE. In vivo anatomy of the Neer and Hawkins sign positions for shoulder impingement. *J Shoulder Elbow Surg*. 2006;15(1):40-49.
31. Petersen B, Nystrom C, Pham T, et al. *Effects of elevation angle and plane of motion on subacromial and internal impingement*. Paper presented at: Proceedings of the VIIIth Conference of the International Shoulder Group. University of Minnesota, Minneapolis, MN. 2010.
32. Pope DP, Croft PR, Pritchard CM, Silman AJ, Macfarlane GJ. Occupational factors related to shoulder pain and disability. *Occup Environ Med*. 1997;54(5):316-321.
33. Punnett L, Fine LJ, Keyserling WM, Herrin GD, Chaffin DB. Shoulder disorders and postural stress in automobile assembly work. *Scand J Work Environ Health*. 2000;26(4):283-291.
34. Roe Y, Bautz-Holter E, Juel NG, Soberg HL. Identification of relevant International Classification of Functioning, Disability and Health categories in patients with shoulder pain: a cross-sectional study. *J Rehabil Med*. 2013;45(7):662-669.
35. Rundquist PJ, Anderson DD, Guanche CA, Ludewig PM. Shoulder kinematics in subjects with frozen shoulder. *Arch Phys Med Rehabil*. 2003;84(10):1473-1479.
36. Sobti A, Cooper C, Inskip H, Searle S, Coggon D. Occupational physical activity and long-term risk of musculoskeletal symptoms: a national survey of post office pensioners. *Am J Ind Med*. 1997;32(1):76-83.
37. Soslowsky LJ, Thomopoulos S, Tun S, et al. Neer Award 1999. Overuse activity injures the supraspinatus tendon in an animal model: a histologic and biomechanical study. *J Shoulder Elbow Surg*. 2000;9(2):79-84.
38. Svendsen SW, Bonde JP, Mathiassen SE, Stengaard-Pedersen K, Frich LH. Work related shoulder disorders: quantitative exposure-response relations with reference to arm posture. *Occup Environ Med*. 2004;61(10):844-853.
39. Walch G, Boileau P, Noel E, Donell ST. Impingement of the deep surface of the supraspinatus tendon on the posterosuperior glenoid rim: an arthroscopic study. *J Shoulder Elbow Surg*. 1992;1(5):238-245.
40. Yamamoto A, Takagishi K, Osawa T, et al. Prevalence and risk factors of a rotator cuff tear in the general population. *J Shoulder Elbow Surg*. 2010;19(1):116-120.