

Henry Ford Health System

## Henry Ford Health System Scholarly Commons

---

Neurosurgery Articles

Neurosurgery

---

2-8-2021

### **Minimally Invasive Techniques for Iliac Bolt Placement: 2-Dimensional Operative Video**

Travis Hamilton

Mohamed Macki

Thomas M. Zervos

Victor Chang

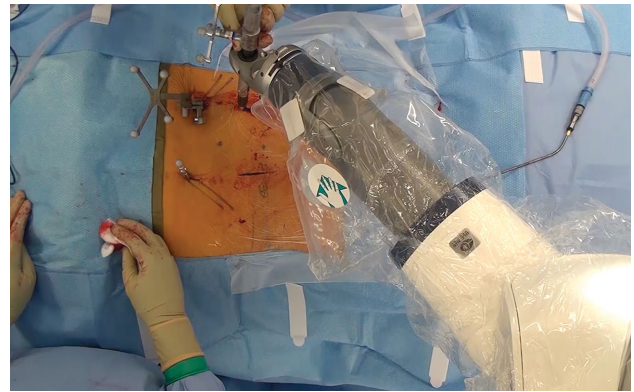
Follow this and additional works at: [https://scholarlycommons.henryford.com/neurosurgery\\_articles](https://scholarlycommons.henryford.com/neurosurgery_articles)

---

# Minimally Invasive Transforaminal Interbody Fusion With Robotically Assisted Bilateral Pedicle Screw Fixation: 2-Dimensional Operative Video

Jakub Godzik, MD\*, Corey T. Walker, MD\*, Nicholas Theodore, MD‡, Juan S. Uribe, MD\*, Steven W. Chang, MD\*, Laura A. Snyder, MD\*

\*Department of Neurosurgery, Barrow Neurological Institute, St. Joseph's Hospital and Medical Center, Phoenix, Arizona; ‡Department of Neurosurgery, John Hopkins University, Baltimore, Maryland



Watch now at <https://academic.oup.com/ons/article-lookup/doi/10.1093/ons/opy288>

**Correspondence:** Laura A. Snyder, MD, c/o Neuroscience Publications; Barrow Neurological Institute, St. Joseph's Hospital and Medical Center, 350 W. Thomas Rd., Phoenix, AZ 85013. E-mail: [Neuropub@barrowneuro.org](mailto:Neuropub@barrowneuro.org)

Minimally invasive surgery (MIS) techniques may enable faster patient recovery and reduce the incidence of postoperative infections. Image-guided approaches to spinal instrumentation and interbody fusion have gained popularity in MIS, reducing radiation exposure and improving screw placement accuracy. Use of a novel computed tomography (CT) navigation-based robotic arm provides for live image-guided surgery, with the potential for augmenting existing MIS approaches and improving the accuracy of instrumentation placement. We report on the surgical technique of MIS transforaminal lumbar interbody fusion (TLIF) performed with the assistance of a new robotic device (ExcelsiusGPS, Globus Medical Inc, Audubon, Pennsylvania) and intraoperative CT guidance in a patient with single-level lumbar spondylolisthesis. The patient gave written informed consent before treatment. Institutional review board approval was deemed unnecessary. The patient was positioned

prone on the operating room table, and an intraoperative CT was obtained with stereotactic arrays placed bilaterally in the posterior superior iliac spine. Screw trajectories were planned using the ExcelsiusGPS software and placed percutaneously with the robotic arm without using a Kirschner wire. Interbody placement was performed via an expandable retractor after muscle dilation. Screw placement accuracy was determined with postoperative CT, which demonstrated good screw positioning without breach. The patient recovered well and was discharged home without complications. The combined use of the new robotic device and intraoperative CT enables accurate and safe fixation for the treatment of symptomatic lumbar spondylolisthesis. The operative video demonstrates the technical nuances of positioning, stereotactic marker placement, work flow, and screw placement.

Used with permission from Barrow Neurological Institute, Phoenix, Arizona.

**KEY WORDS:** Image-guided navigation, Lumbar, Minimally invasive surgery, Robotic arm, Pedicle screw, Transforaminal lumbar interbody fusion

*Operative Neurosurgery* 16:E86–E87, 2019

DOI:10.1093/ons/opy288

Received, February 19, 2018. Accepted, August 22, 2018. Published Online, September 24, 2018.

## Disclosures

Dr Theodore is entitled to royalties on future sales of the ExcelsiusGPS (Globus Medical Inc), is a consultant for and owns stock in Globus Medical Inc, and receives royalties from Depuy-Synthes Companies. Dr Chang, receives

royalties from Globus Medical Inc. Dr Snyder is a consultant for Globus Medical, Inc. The other authors have no personal, financial, or institutional interest in any of the drugs, materials, or devices described in this article. Dr Uribe is a consultant for, receives royalties from, and has received research grants from NuVasive Inc.

## Acknowledgments

We thank the staff of Neuroscience Publications at Barrow Neurological Institute for assistance with manuscript and video preparation. We thank Gary Armstrong for intraoperative photography.

planning software, technical steps, and operative nuances are all nicely demonstrated. This video will be a useful aid for trainees and surgeons gaining early clinical experience with this technology.

## COMMENT

**T**he authors effectively demonstrate a MIS-TLIF procedure using robotically-assisted pedicle screw and rod fixation. The surgical

**Matthew T. Neal**

*Winston-Salem, North Carolina*