

Henry Ford Health System

Henry Ford Health System Scholarly Commons

Dermatology Articles

Dermatology

9-14-2020

Elderly Man With Progressive Nail Atrophy: Challenge

Ogochukwu Nefertiti Umeh

Ryan Beekman

Helen D'Sa

Ben J Friedman

Follow this and additional works at: https://scholarlycommons.henryford.com/dermatology_articles

Elderly Man With Progressive Nail Atrophy: Challenge

Ogochukwu Nefertiti Umeh, BS, MS,* Ryan Beekman, MD,† Helen D’sa, DO,‡ and Ben J. Friedman, MD§¶

(*Am J Dermatopathol* 2020;00:1)

CASE

A 61-year-old man with a medical history of recent onset iron-deficiency anemia, congestive heart failure, and peptic ulcer disease presented to our clinic complaining of a 2-year history of progressively worsening 20-nail dystrophy. He had seen several other providers in the preceding months complaining of fatigue, xerophthalmia, dysarthria, dysphagia, easy bruising, and chronic diarrhea without a clear diagnosis. Upper endoscopy and colonoscopy 6 months before failed to detect any abnormalities.

Physical examination of the digits revealed periungual erythema with frayed cuticles and rough, atrophic nail plates (Fig. 1).

Biopsy of the nail bed was obtained for histopathologic evaluation (Fig. 2).

WHAT IS YOUR DIAGNOSIS?

(Continued on page XXX)

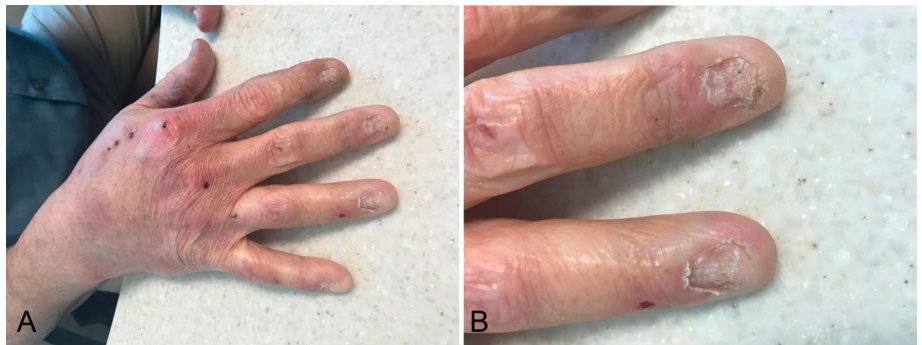

FIGURE 1. Clinical photograph. A, Dorsal hand. B, Close-up of nails.

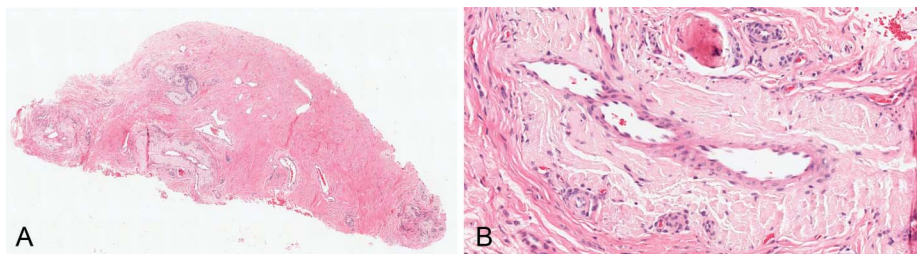


FIGURE 2. Histopathology. A, H&E, original magnification, $\times 100$. B, H&E, original magnification $\times 400$.

From the *St. George’s University School of Medicine, Grenada, West Indies; †Departments of Orthopedics, and ‡Dermatology, Henry Ford Allegiance Health, Jackson, MI; §Department of Dermatology, Henry Ford Health System, Detroit, MI; and ¶Department of Pathology and Laboratory Medicine, Henry Ford Health System, Detroit, MI.

The authors declare no conflicts of interest.

Correspondence: Ben J. Friedman, MD, 3031 West Grand Blvd, Ste 800, Detroit, MI 48202 (e-mail: bfriedm1@hfhs.org).

Copyright © 2020 Wolters Kluwer Health, Inc. All rights reserved.