

Henry Ford Health

Henry Ford Health Scholarly Commons

Cardiology Articles

Cardiology/Cardiovascular Research

9-1-2022

A hybrid subcutaneous and epicardial biventricular implantable cardiac defibrillator with an abdominal generator

Mohamed Raad

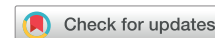Kyle Miletic

Arfaat Khan

Waddah Maskoun

Follow this and additional works at: https://scholarlycommons.henryford.com/cardiology_articles

A hybrid subcutaneous and epicardial biventricular implantable cardiac defibrillator with an abdominal generator



Mohamad Raad, MD,* Kyle Miletic, MD,[†] Arfaat Khan, MD,*
Waddah Maskoun, MD, FHRS*

From the *Division of Electrophysiology, Department of Cardiovascular Diseases, Henry Ford Health System, Detroit, Michigan, and [†]Division of Cardiothoracic Surgery, Department of Cardiovascular Diseases, Henry Ford Health System, Detroit, Michigan.

Introduction

Cardiac resynchronization therapy-defibrillator (CRT-D) devices are indicated for patients with moderate-to-severe left ventricular (LV) dysfunction to restore cardiac function, improve symptoms, and reduce morbidity and mortality.^{1,2} LV resynchronization is traditionally achieved through a pacing lead through the coronary sinus to a lateral branch and the defibrillator lead in the right ventricular (RV) apex. However, there is an ~8% technique failure rate,³ in addition to patients who do not have favorable anatomy for a traditional approach like mechanical tricuspid valve, as well as patients who experience recurrent device infection endocarditis. Several hybrid approaches for CRT-D placement are not uncommon. We describe a case of a patient with various prior episodes of device endocarditis and limited transvenous options who has an indication for CRT-D device placement.

Case report

The patient is a 55-year-old woman with diabetes mellitus, coronary artery disease, long QT syndrome with ventricular tachycardia, LV systolic dysfunction, and permanent atrial fibrillation. She previously had a left-sided implantable cardiac defibrillator (ICD) implanted initially in 2001 (with generator change in 2010), complicated by a high burden of RV pacing with consequent severe LV dysfunction requiring biventricular (BiV) upgrade in 2015 with normalization of LV function. She later developed endocarditis and pocket infection requiring extraction and reimplantation of a right-sided BiV ICD in 2018 (Figure 1A). The left-sided pocket was debrided, resulting in extensive scarring. The

KEYWORDS Epicardial leads; Hybrid surgical/subcutaneous; Endocarditis; Resynchronization therapy; Abdominal generator (Heart Rhythm Case Reports 2022;8:655–657)

Funding Sources: None. Disclosures: All authors have no disclosures or conflicts of interests. **Address reprint requests and correspondence:** Dr Waddah Maskoun, Division of Electrophysiology, Department of Cardiology, Henry Ford Hospital, 2799 W. Grand Blvd, Detroit, MI 48202. E-mail address: wmaskou1@hfhs.org.

KEY TEACHING POINTS

- Recurrent device infection and endocarditis are not uncommon and still the most important limiting factor when considering subcutaneous-transvenous device placement.
- Various approaches to left ventricular resynchronization therapy are available for patients in whom resynchronization therapy is indicated, and minimally invasive surgical approach is a valuable alternative approach when the routine subcutaneous-transvenous system is not optional.
- A hybrid subcutaneous (over the sternum)/surgical biventricular epicardial cardiac resynchronization therapy-defibrillator system using a minimally invasive minithoracotomy with epicardial pacing and subcutaneous implantable cardiac defibrillator leads connected to a single abdominal generator is a novel approach for patients with limited bilateral transvenous anatomy and failed defibrillation threshold testing with an epicardial system.

patient responded to resynchronization therapy with both devices, with borderline normal LV systolic function over several years.

She is now admitted with methicillin-resistant *Staphylococcus aureus* bacteremia. Her echocardiogram revealed vegetations on the atrial lead. She was therefore referred to our center for device extraction and further management.

Her device was interrogated. Upon decreasing of the lower ventricular rate, she had frequent polymorphic premature ventricular complexes, nonsustained polymorphic ventricular tachycardia, and ventricular fibrillation (Figure 1B) requiring appropriate ICD shock by the bedside. Her ventricular arrhythmias were suppressed with BiV pacing. A BiV-ICD system was recommended.

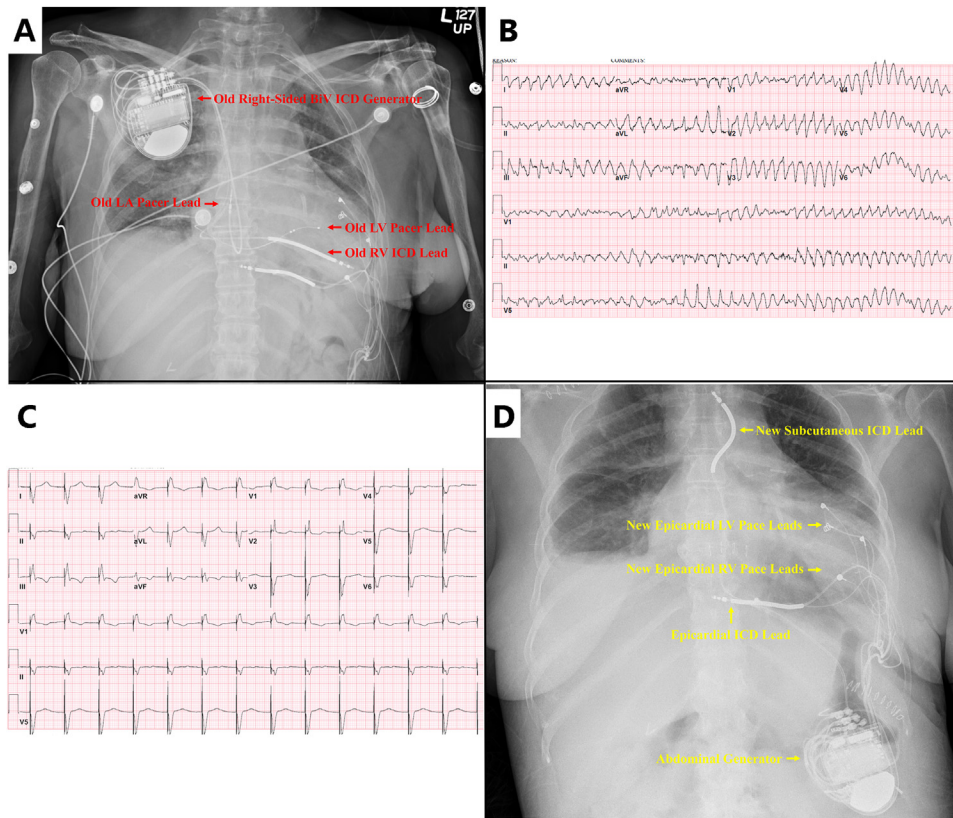


Figure 1 A: Old right-sided biventricular (BiV) implantable cardiac defibrillator (ICD) with new epicardial cardiac resynchronization therapy-defibrillator (CRT-D) system. B: Ventricular fibrillation. C: Biventricular pacing with QRS 110 ms. D: New hybrid epicardial and subcutaneous biventricular ICD. LA = left atrial; LV = left ventricular; RV = right ventricular.

Given her limited transvenous access, we implanted an epicardial BiV pacing system with 1 pericardial coil (DF1 model 6935; Medtronic, Minneapolis, MN) using a minithoracotomy at the left fifth intercostal space (Supplemental Figure 1, label D). We implanted 2 epicardial LV (Medtronic 4968-60 and Medtronic 5071-53) and 2 RV leads (Medtronic 4968-60) in case of ventricular lead failure in the future. All leads had normal pacing and sensing thresholds. Only 1 ICD coil (Medtronic 693565) lead along the base of the heart could be placed, as the posterior epicardial space could not be accessed further. The leads were capped and tunneled to an abdominal pocket. We considered a subcutaneous ICD as an alternative approach for the ICD part. However, since the subcutaneous ICD system relies on preimplantation QRS-T morphology screening to assure it will reliably detect QRS complexes and T waves, we elected to place the epicardial ICD coil at the time of her surgery in case if she failed the screening and the need for a second cardiac surgery in this case.

The patient was brought later for a generator placement with defibrillation threshold (DFT) testing and the possible addition of subcutaneous coil (Figure 1A). DFT testing using the current epicardial system was unsuccessful. A DF1 lead (Medtronic 6935-58) was tunneled and placed subcutaneously over the sternum. The coil was connected to the generator (Medtronic DTPB2D1), and the pace-sense part was capped. There was good BiV-pacing (Figure 1C), and her

DFT testing after including the new subcutaneous coil was successful. Her right-sided BiV-ICD was successfully extracted afterward (Figure 1D) using serial gentle traction technique for the LV and right atrial lead. The ICD lead required an EZ locking stylet with serial gentle traction. There were no periprocedural complications. She was discharged on a prolonged course of 8 weeks of intravenous antibiotics. Her device function was normal at 6 weeks follow-up, and her echocardiogram revealed an unchanged borderline normal LV systolic function with no pericardial effusion.

Discussion

Surgical approaches for epicardial ICD lead implantation have been extensively described with various surgical techniques and hybrid approaches.⁴ Most epicardial CRT-D devices require a mid-sternotomy approach with generator commonly placed in the left or right pectoral area.⁴ To our knowledge only 2 published cases for adults with completely epicardial implantable CRT-D devices have been placed using a minithoracotomy approach with 2 epicardial ICD coils and abdominal generator. In the first case, a right atrial lead was not required, similar to our patient, and in the second case a robotic system approach was used.^{4,5} To our knowledge, we report the first case of a hybrid subcutaneous/surgical BiV-CRT-D system with epicardial and subcutaneous ICD leads connected to a single abdominal generator using a minimally invasive surgical approach.

DFT testing was not successful in our case, likely because of the location and short distance between the RV-ICD coil and the generator, with the defibrillation vector likely not traversing through sufficient myocardial tissue. We may have avoided this obstacle had a second posterior or posterolateral ICD coil lead been successfully implanted along the base of the heart at the time of surgery. This option was not available to us in this case, as it would have required further extension of the surgical incision or full midsternal thoracotomy approach, per our surgical team. We could also avoid the need for the parasternal coil if the generator could be placed in the left upper chest position, but this was not a feasible option, given her history of a prior pocket infection with extensive debridement and scar tissue. Furthermore, considering a more lateral midaxillary location for the ICD might allow for better shock vector. However, we felt that the parasternal ICD lead/coil would still be needed for successful DFT, and since the DFT testing was successful after that we did not consider moving the generator to the lateral midaxillary line. Finally, and in retrospect, both procedures could have been combined in an electrophysiology / cardiac surgery team approach. Nonetheless, careful presurgical planning is warranted in such complicated multi-approach procedures.

Conclusion

We describe a case of a patient who required CRT-D therapy with multiple prior CRT-D device endocarditis and pocket infection. We used a novel alternative implantation approach

using a minimally invasive minithoracotomy for a hybrid surgical epicardial BiV CRT-D system and subcutaneous (above the sternum) ICD lead connected to a single abdominal generator.

Appendix Supplementary data

Supplementary data associated with this article can be found in the online version at <https://doi.org/10.1016/j.hrcr.2022.07.002>.

References

1. Epstein AE, DiMarco JP, Ellenbogen KA, et al. 2012 ACCF/AHA/HRS focused update incorporated into the ACCF/AHA/HRS 2008 guidelines for device-based therapy of cardiac rhythm abnormalities: a report of the American College of Cardiology Foundation/American Heart Association Task Force on Practice Guidelines and the Heart Rhythm Society. *Circulation* 2013;127:e283–e352.
2. Glikson M, Nielsen JC, Kronborg MB, et al. 2021 ESC Guidelines on cardiac pacing and cardiac resynchronization therapy. *Eur Heart J* 2021;42:3427–3520.
3. Cazeau S, Leclercq C, Lavergne T, et al. Effects of multisite biventricular pacing in patients with heart failure and intraventricular conduction delay. *N Engl J Med* 2001;344:873–880.
4. Tonko JB, Blauth C, Rosenthal E, Rinaldi CA. Completely epicardial implantable cardioverter/defibrillator (ICD) and CRT-D systems: a case series and systematic literature review. *Pacing Clin Electrophysiol* 2021;44:1616–1630.
5. Amraoui S, Labrousse L, Jansens J-L, Sohal M, Bordachar P, Ritter P. Implantation of a cardiac resynchronization therapy and defibrillation system using a robotic approach. *HeartRhythm Case Rep* 2015;1:356–359.