

5-2019

Infliximab-Induced Arthralgia

Allan Brazier

Guneet Ahluwalia
Henry Ford Health System

Tushar Shetty
Henry Ford Health System

Alexis Haftka-George
Henry Ford Health System

Follow this and additional works at: <https://scholarlycommons.henryford.com/merf2019caserpt>

Recommended Citation

Brazier, Allan; Ahluwalia, Guneet; Shetty, Tushar; and Haftka-George, Alexis, "Infliximab-Induced Arthralgia" (2019). *Case Reports*. 126.

<https://scholarlycommons.henryford.com/merf2019caserpt/126>

This Poster is brought to you for free and open access by the Medical Education Research Forum 2019 at Henry Ford Health System Scholarly Commons. It has been accepted for inclusion in Case Reports by an authorized administrator of Henry Ford Health System Scholarly Commons. For more information, please contact acabrer4@hfs.org.



Abstract

Case Presentation: A 23-year-old Caucasian female with a medical history of ulcerative colitis presented with erythematous, painful metacarpal joints and jaw pain. She had associated symptoms of fatigue, chills, and dyspnea. Her history included Crohn’s disease status post-proctocolectomy, primary sclerosing cholangitis, and hypothyroidism. Admission laboratory studies demonstrated mild hypokalemia, elevated alkaline phosphatase, and elevated sedimentation rate. Physical exam showed a fatigued female with bilateral metacarpal joints arthralgias, shoulder weakness more pronounced on the right, and decreased upper extremity range of motion secondary to pain. She was diagnosed with ulcerative colitis 2 years prior and failed all previous treatments; therefore, she was given infliximab 9 days before her presentation. She had previously received at least 2 doses of infliximab 12 years prior to her ulcerative colitis. Prior to initiating treatment, she had no antibodies to infliximab and had negative tests for tuberculosis and hepatitis B. Laboratory findings were negative for antinuclear antibodies and weakly positive for anti-histone antibodies. Infliximab was held, while providing close monitoring along with proper hydration and management of symptoms. She made significant recovery within 36 hours. A diagnosis of infliximab-induced arthralgias was made.

Discussion: Recognizing tumor necrosis factor- α 's vital role in inflammatory response inhibitors have been effective treatments in inflammatory conditions such as inflammatory bowel disease, rheumatoid arthritis, spondyloarthropathies, and psoriasis. Infusion reactions with infliximab are the most common adverse effects, with an overall incidence of 5.2-6.2 per 100 patient-years. They can be subdivided into acute infusion reactions or delayed infusion reactions. Acute reactions represent type 1 hypersensitivity reactions mediated by immunoglobulin E, but true anaphylactic reactions to infliximab are uncommon. Delayed infusion reactions resemble type 3 hypersensitivity reactions, usually between 1-14 days after start of treatment, but can occur up to 24 weeks after administration. Immune complexes can cause systemic effects such as acute serum sickness, resulting in fever, pruritic skin rash, and arthralgias.

Conclusions: Infusion reactions can occur even if there are no preexisting antibodies to infliximab. Although there are recommendations for dampening infusion reactions, they are not guaranteed to prevent them. It is important to monitor patients for 1-3 weeks after infliximab infusions for serum sickness type symptoms.

Introduction

- Infliximab is a monoclonal antibody that acts as a TNF-alpha inhibitor
- It is often used in the treatment of illnesses such as inflammatory bowel disease and rheumatoid arthritis
- The drug has been associated with both immediate infusion reactions (within 1-2 hours) and late infusion reactions (after 24 hours) such as serum sickness
 - If pre-existing anti-drug antibodies are absent, serum sickness usually develops 1-3 weeks after drug administration
 - If anti-drug antibodies are present, the reactions can develop sooner
- Malaise, fever, polyarthralgia, and jaw pain are often seen in late infusion reactions

Pictures

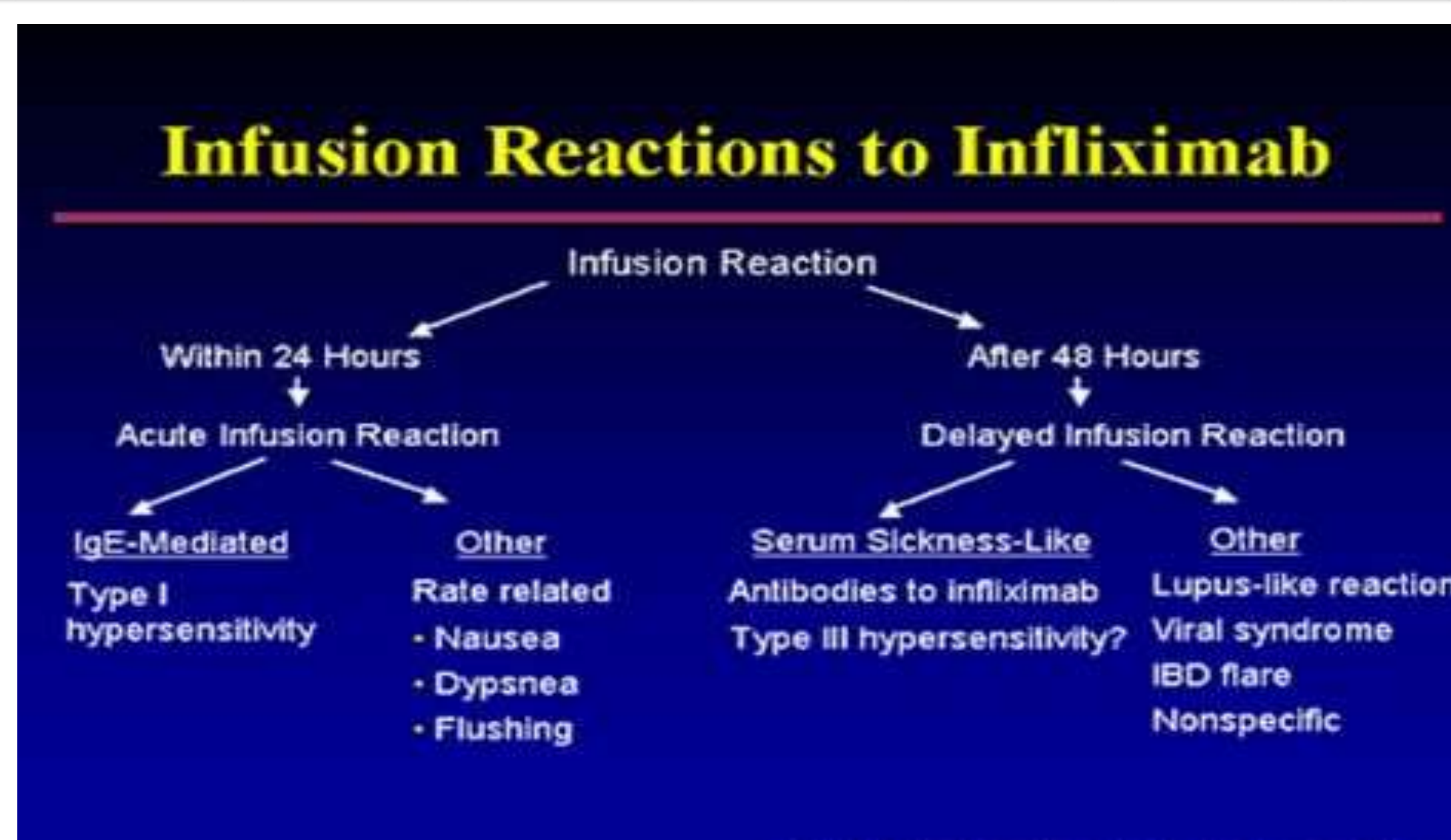


Figure1 : Infusion Reactions to Infliximab Flow Chart

Patient Description

- 23 year old female with history of ulcerative colitis (UC)
- Also, Crohn’s disease status post proctocolectomy, primary sclerosing cholangitis, and hypothyroidism
- Presented with erythematous, painful metacarpal joints, jaw pain, and fatigue
- PE: bilateral MC joint arthralgias and erythema along with shoulder weakness
- Had received infliximab 12 years prior for Crohn’s disease
- Diagnosed with UC 2 years prior and had failed previous treatments
- Was given infliximab 9 days prior to presentation
- Lab findings were negative for antinuclear antibodies and weakly positive for anti-histone antibodies

Selected Lab Values

Test	Value
CMP	Potassium: 3.3 mmol/L Alk Phosphatase: 235 IU/L ALT
CBC	Within Normal Limits
ESR	49 mm/hr (reference: < 20 mm/hr)
ANA	Negative
C-ANCA	< 1:20 (reference < 1:20)
DNA Antibody Screen	Negative
Histone Ab	1.9 (reference: <1.0 units)
P-ANCA	< 1:20 (reference: <1:20)
Rf by Nephelometry	<10 (reference: <14 IU/mL)
EBV Nuclear Antibody	Negative

Interventions

- Rheumatology consult
- Recommend checking autoimmune labs
- Noted that ANA can be positive due to IBD alone
- X-ray of bilateral hands → negative for inflammatory arthritis; demonstrated swelling of right thumb IP joint
- IV hydration and pain management
- Monitor for response

Response to Treatment

- Patient recovered within 36 hours of treatment
- Pain, fatigue, symptoms subsided

Discussion

- Acute reactions represent type 1 HS reactions mediated by IgE, although true anaphylactic reactions are rare
- Delayed infusion reactions resemble type 3 HS reactions, often between 1-14 days after treatment begins
- Immune complexes can result in systemic effects such as acute onset serum sickness, resulting in fever, pruritic rash, and arthralgias

Conclusions

- Infusion reactions can occur with or without pre-existing antibodies to infliximab
- Although recommendations exist for dampening infusion reactions, prevention is not guaranteed
- Patients should be monitored for 1-3 weeks after infliximab infusions

Sample Bibliography

1. Almoallim, Hani et al. “Anti-Tumor Necrosis Factor-A Induced Systemic Lupus Erythematosus.” *The Open Rheumatology Journal* 6 (2012): 315–319. *PMC*. Web. 3 Aug. 2018.
2. “Infliximab.” ClinicalKey, Sladen Libraries, https://www.clinicalkey.com/#!/content/drug_monograph/6-s2.0-2284?scrollTo=%23References
3. “Infliximab (Including Biosimilars of Infliximab): Drug Information.” *UpToDate*, https://www.uptodate.com/contents/infliximab-including-biosimilars-of-infliximab-drug-information?search=remicade&source=search_result&selectedTitle=1~148&usage_type=default&display_rank=1
4. Lichtenstein, Lev et al. “Infliximab-Related Infusion Reactions: Systematic Review.” *Journal of Crohn’s & Colitis* 9.9 (2015): 806–815. *PMC*. Web. 3 Aug. 2018.
5. Merola, Joseph F, et al. “Drug-Induced Lupus.” *UpToDate*, 11 Jan. 2017, www.uptodate.com/contents/drug-induced-lupus#H359552195.