

Henry Ford Health System

Henry Ford Health System Scholarly Commons

Clinical Research

Medical Education Research Forum 2019

5-2019

Success Rate of Embolization for Type II Endoleaks at a Major Tertiary Referral Center

Garret Greer

Henry Ford Health System, garretg@rad.hfh.edu

Brian Sullivan

Henry Ford Health System, bsulliv5@hfhs.org

Ziad Al Adas

Henry Ford Health System

Mitchell R Weaver

Henry Ford Health System, mweaver1@hfhs.org

David W McVinnie

Henry Ford Health System, davidm@rad.hfh.edu

See next page for additional authors

Follow this and additional works at: <https://scholarlycommons.henryford.com/merf2019clinres>

Recommended Citation

Greer, Garret; Sullivan, Brian; Al Adas, Ziad; Weaver, Mitchell R; McVinnie, David W; Nypaver, Timothy J; Shepard, Alexander D.; and Kabbani, Loay S, "Success Rate of Embolization for Type II Endoleaks at a Major Tertiary Referral Center" (2019). *Clinical Research*. 27.

<https://scholarlycommons.henryford.com/merf2019clinres/27>

This Poster is brought to you for free and open access by the Medical Education Research Forum 2019 at Henry Ford Health System Scholarly Commons. It has been accepted for inclusion in Clinical Research by an authorized administrator of Henry Ford Health System Scholarly Commons.

Authors

Garret Greer, Brian Sullivan, Ziad Al Adas, Mitchell R Weaver, David W McVinnie, Timothy J Nypaver, Alexander D. Shepard, and Loay S Kabbani

Success Rate for Embolization of Type II Endoleaks at a Major Tertiary Referral Center

**Garret Greer, DO, Brian P Sullivan, M.Sc,
Ziad Al-Adas, MD, Mitchell Weaver, MD,
David McVinnie, MD, Timothy Nypaver,
MD, Alexander Shepard, MD, Loay S.
Kabbani, MD**

Departments of Interventional Radiology and Vascular Surgery

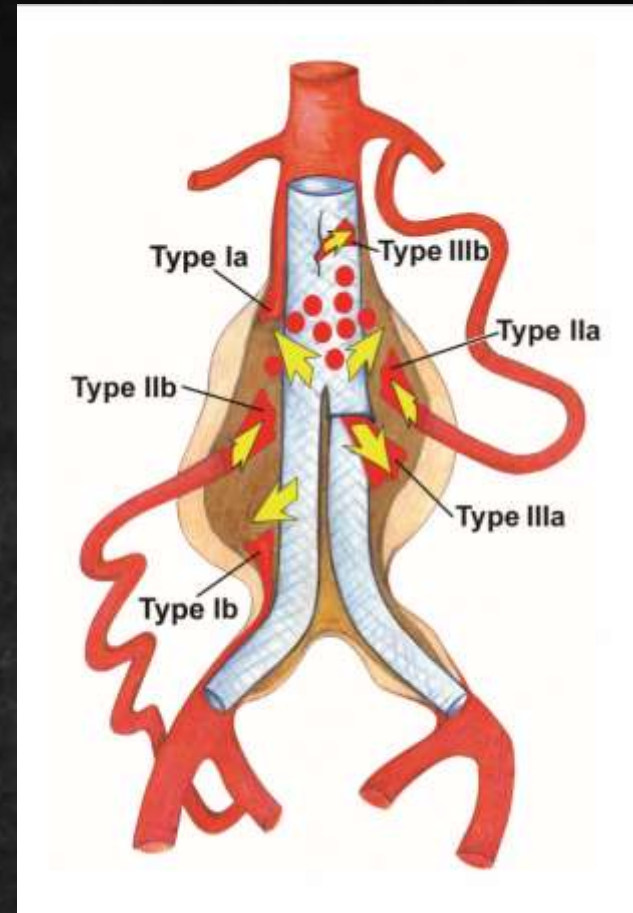
Henry Ford Hospital

Detroit, Michigan



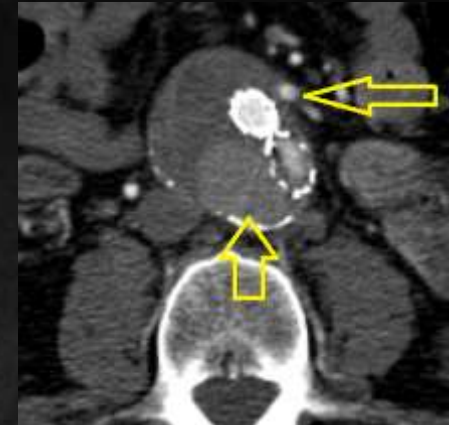Introduction:

- Endovascular aneurysm repair (EVAR) has become the mainstay in the treatment of abdominal aortic aneurysms (AAA).
- EVAR requires lifetime follow up imaging to monitor for signs of endograft migration and development of endoleaks, which occur in upwards of 20-25% of EVARs.
- Type II endoleaks (T2EL) are the most frequent type of endoleak and are estimated to account for 40% of all endoleaks^{4, 5}. T2EL occur due to retrograde flow into the aneurysmal sac through collateral circulation, most commonly from the lumbar arteries and the IMA^{5, 6}.
- Although T2EL may spontaneously resolve, persistent leaks associated with increased aneurysm sac growth often require intervention¹.
- Several studies have shown that embolization of the aneurysm sac and/or collateral vessels can adequately disrupt the offending vessels and prevent further sac expansion and is an effective treatment for T2EL²⁻⁶.

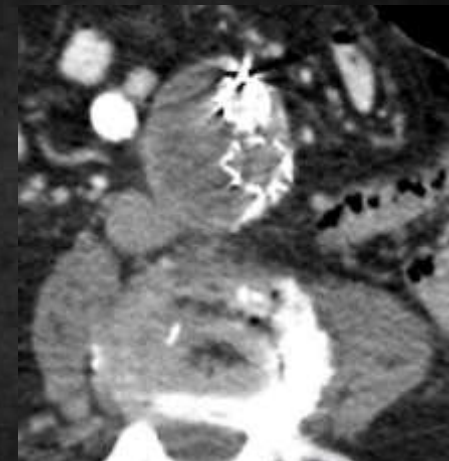


Study Objectives:

- *Primary Objective:*
 - Assess our institutional rate of success with first embolization of isolated type II endoleaks.
- *Secondary Objectives:*
 - Characterize the population afflicted by type II endoleaks.
 - Examine the effect(s) of inflow vessel, embolization site, and embolization method on success of embolization.
 - Determine the outcomes of patients who failed initial embolization of type II endoleaks.



Above: T2EL via patent IMA.



Above: Same patient 4 years later s/p embolization of IMA. Cessation of growth after IMA successfully occluded.

Methods

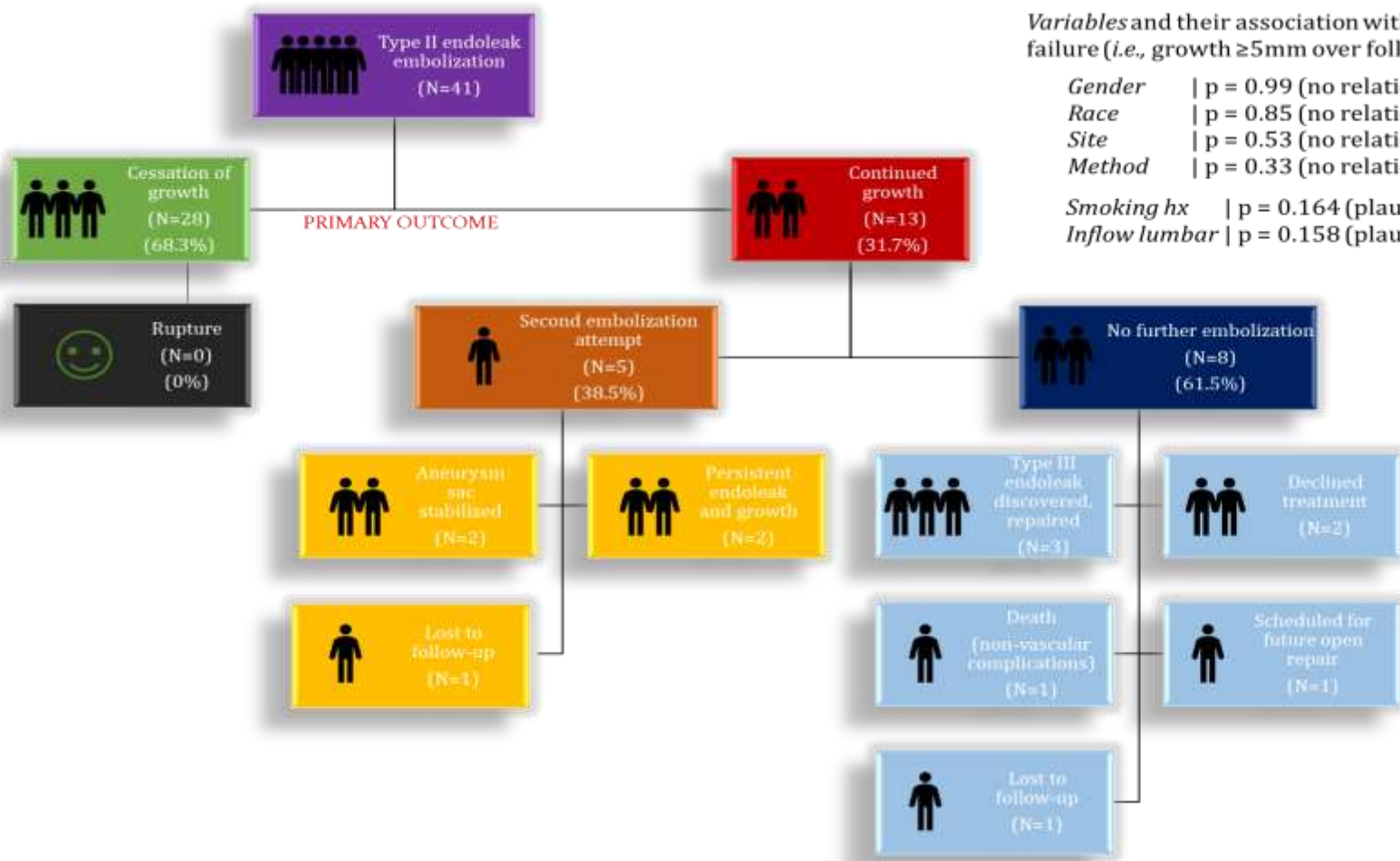
1. The Institutional Radiology database at our tertiary referral hospital was queried for type II endoleak during the period 2006-2018. (N=92)
2. A retrospective chart review was then carried out. Only patients who underwent embolization for isolated type 2 endoleaks and had follow-up imaging were analyzed (N=92 to N=41).
3. The follow-up period was defined as the interval between EVAR and most recent aortic imaging study.
4. The **primary outcome** was success of the endoleak repair as determined by cessation of growth of the native aneurysm sac (i.e., ≤ 5 mm change in diameter over follow-up period).
5. Data pertaining to patient demographics, location of the endoleak, type of occlusion performed, type of endograft used for EVAR, and incidence of aneurysm rupture were collected as secondary measures.

Patient Analysis:

Variable	Value
Age at AAA repair (years \pm sd)	75.66 \pm 7.62 years
Average follow-up (months)	62.65 months
Smoking History (%)	28/41 (68.3%) positive
Hyperlipidemia (%)	37/41 (90.2%) positive
Hypertension (%)	36/41 (87.8%) positive
Sex (%)	33/41 (71.7%) male
Race (%)	30/40 (75.0%) white 8/40 (20.0%) black 2/40 (5.0%) other
Inflow vessel (%)	17/39 (43.7%) lumbar only 13/39 (33.3%) IMA only 13/39 (33.3%) mix or other
Embolization site (%)	16/37 (43.2%) vessel only 5/37 (13.5%) cavity only 19/42 (43.2%) mix
Embolization method (%)	24/37 (64.9%) coil 3/37 (8.1%) glue 10/37 (27.0%) mix

Results:

- 41 patients were treated for isolated type II endoleaks and had adequate follow-up for inclusion in the study.
 - Mean follow-up was 62 months (~5 years).
 - Demographics are shown in the table.
-
- Cessation of growth was achieved in 28/41 (68.3%) of the patients after one embolization procedure. In 13/41 (31.5%) of patients, growth of the native aneurysm sac continued.
 - Of the patients whose aneurysms continued to grow, 8/13 (61.5%) did not undergo a second embolization. The remaining 5/13 (38.5%) underwent a second embolization.
- In patients who failed embolization, 3/13 (23.1%) were eventually found to have a type 3 endoleak on follow-up imaging.
- Smoking history and inflow through lumbar arteries show a closer relationship to failure of embolization than do gender, race, site of embolization, or type of embolization.



Variables and their association with embolization failure (i.e., growth ≥5mm over follow-up period):

- Gender | p = 0.99 (no relationship)
- Race | p = 0.85 (no relationship)
- Site | p = 0.53 (no relationship)
- Method | p = 0.33 (no relationship)
- Smoking hx | p = 0.164 (plausible correlation)
- Inflow lumbar | p = 0.158 (plausible correlation)

Limitations:

- Retrospective observational study.
- Data represents a single institutions experience.
- As a result of the strict inclusion criteria used for isolated type II endoleaks with follow-up, the overall study power was low.

Conclusions:

- **First embolization is successful in halting growth of the aneurysm sac in 68.3% of isolated type II endoleaks over a 5 year follow-up period.**
- **A history of smoking and a lumbar inflow vessel may predict a more challenging embolization with higher failure rate.**
- **The site of embolization (intra-vessel, intra-cavity, or both) does not significantly impact the rate of success.**
- **Caution must be taken to make sure the patients do not have an occult type I or type III endoleak.**



References:

1. Batti S, Cochenec F, Roudot-Thoraval F, Becquemin JP. Type II Endoleaks After Endovascular Repair of Abdominal Aortic Aneurysm are not Always a Benign Condition. *Journal of Vasc Surg.* 2013; 57 (5); 1291-1297.
2. Baum R, Stavropoulous W. Management of Type II Endoleaks: Embolization, Sac Injection and Watchful Waiting. *JVIR.* 2005; 16(2):174-8.
3. Funaki B, Birouti N, Zangan SM, Van Ha TG, et al. Evaluation and Treatment of Suspected Type II Endoleaks in Patients with Enlarging Abdominal Aortic Aneurysms. *JVIR.* 2012; 23(7):866-72
4. Ghandi, R, Bryce Y, Ganguli S, McWilliams J, Vatakencherry G. Management of Type II Endoleaks: Available Options for Treating the Most Common Type of Endoleak After EVAR. *Endovascular Today.* 2016; 15(4). Online publication.
5. Rahimi S, Nassiri N, Huntress L, Crystal D, Thomas J, Shafritz R, et al. An Institution-Wide Algorithm for Treatment of Type II Endoleak Following Endovascular Aneurysm Repair (EVAR). *Journal of Vascular and Endovascular Surgery.* 2018; early online access, not yet in print.
6. Samura M, Morikage N, Mizoguchi T, Takeuchi Y, Ueda K, et al. Identification and Anatomical Risk Factors for Type II Endoleak to Guide Selective Inferior Mesenteric Artery Embolization. *Ann Vasc Surg.* 2018; 48: 166-173