

Henry Ford Health System

Henry Ford Health System Scholarly Commons

Case Reports

Medical Education Research Forum 2020

5-2020

C3 Glomerulonephritis: A Rare Case of GN

Stanley Linder
slinder1@hfhs.org

Hesham Shaban
Henry Ford Health System, hshaban1@hfhs.org

Follow this and additional works at: <https://scholarlycommons.henryford.com/merf2020caserpt>

Recommended Citation

Linder, Stanley and Shaban, Hesham, "C3 Glomerulonephritis: A Rare Case of GN" (2020). *Case Reports*. 57.

<https://scholarlycommons.henryford.com/merf2020caserpt/57>

This Poster is brought to you for free and open access by the Medical Education Research Forum 2020 at Henry Ford Health System Scholarly Commons. It has been accepted for inclusion in Case Reports by an authorized administrator of Henry Ford Health System Scholarly Commons.



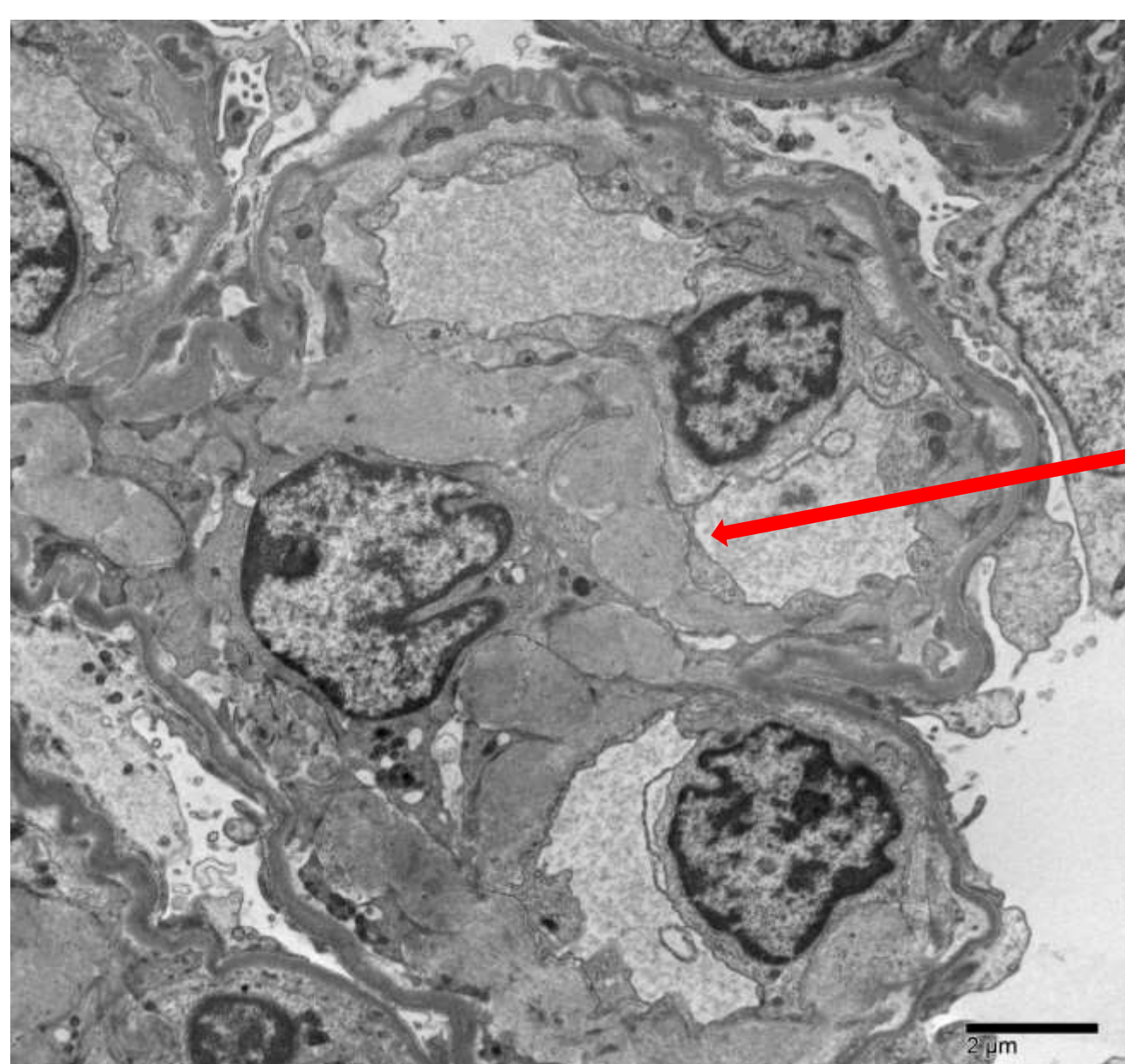
Introduction

C3 Glomerulonephritis has undergone a recent change in its definition since its consensus review in 2013. Prior to 2013, C3GN would have been classified morphologically as a Type 3 Membranoproliferative Glomerulonephritis with the classic pathologic feature of double contoured Basement Membrane which is notable in all MPGN types. It is relatively rare phenomenon affecting 1-2/1,000,000 cases in the US, based on registry data involving an overactivation of the Alternative Complement System.

Case

A 71 year old woman with a past medical history of Hepatitis C with more than 1.5 million viral copies was admitted with lower extremity edema, urinary retention, and CHF exacerbation with notable sacral edema. The admission also resulted in an acute kidney injury which was initially thought to be a component of aggressive diuresis. Nephrology was consulted and urine studies were obtained. The patient was noted to have nephrotic range proteinuria over 8 grams/gram and hematuria. Glomerulonephritis was a major concern given her Hepatitis C diagnosis. Serologies were obtained. Laboratory studies were consistent with a possible Cryoglobulinemic Glomerulonephritis with undetectable C4 levels, low C3 levels, and an elevated Rheumatoid Factor. While waiting for Cryoglobulin levels to return, the patient underwent a kidney biopsy to confirm the suspected diagnosis.

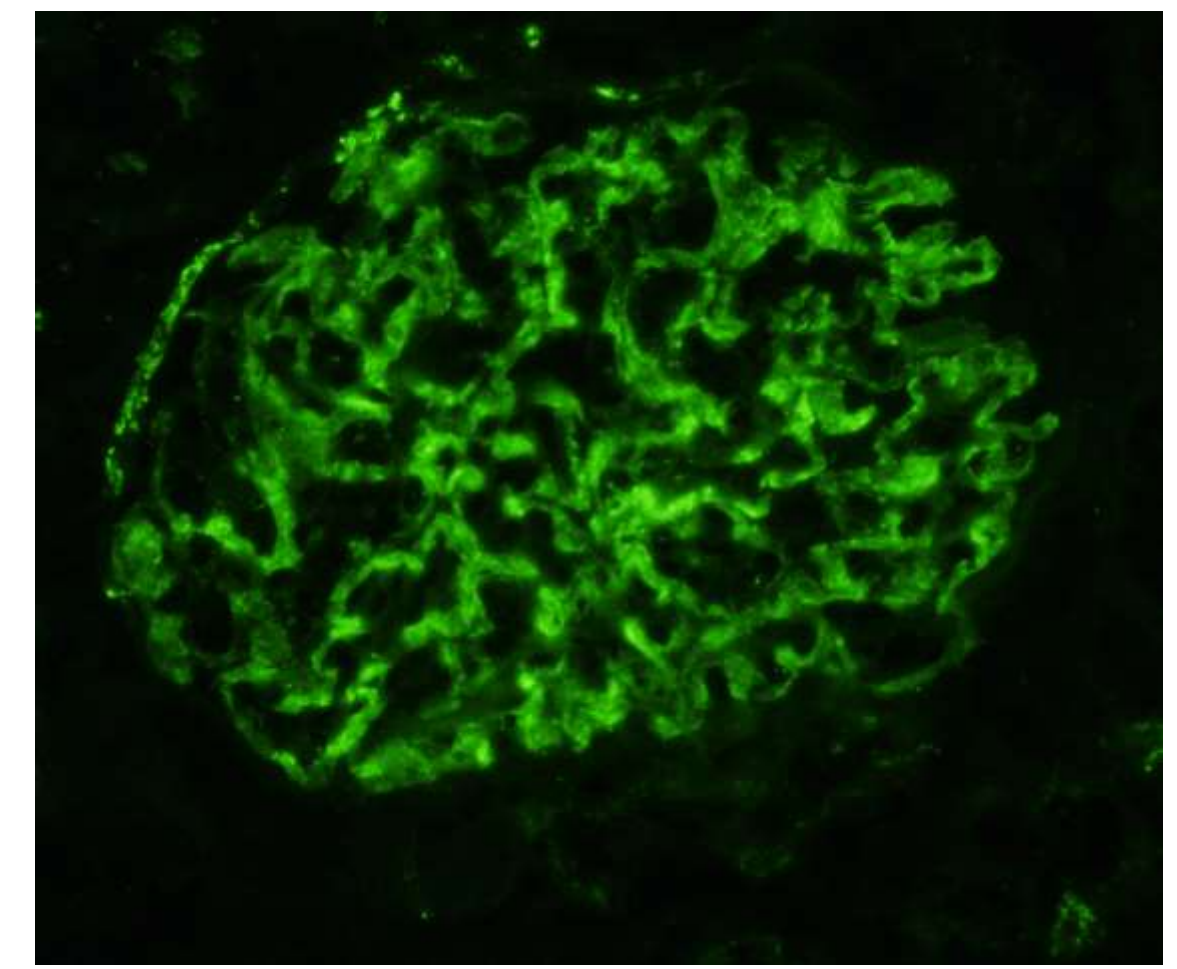
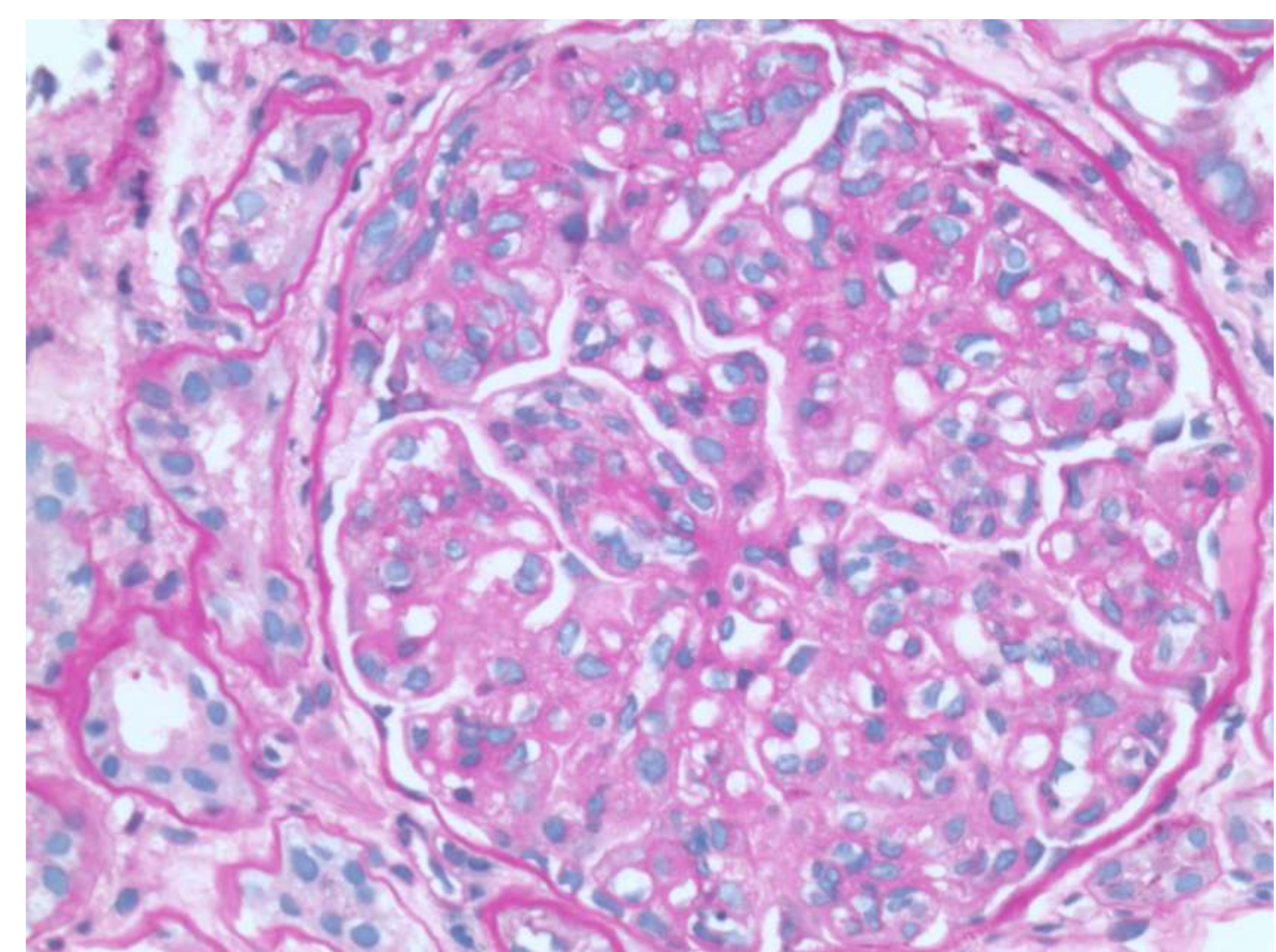
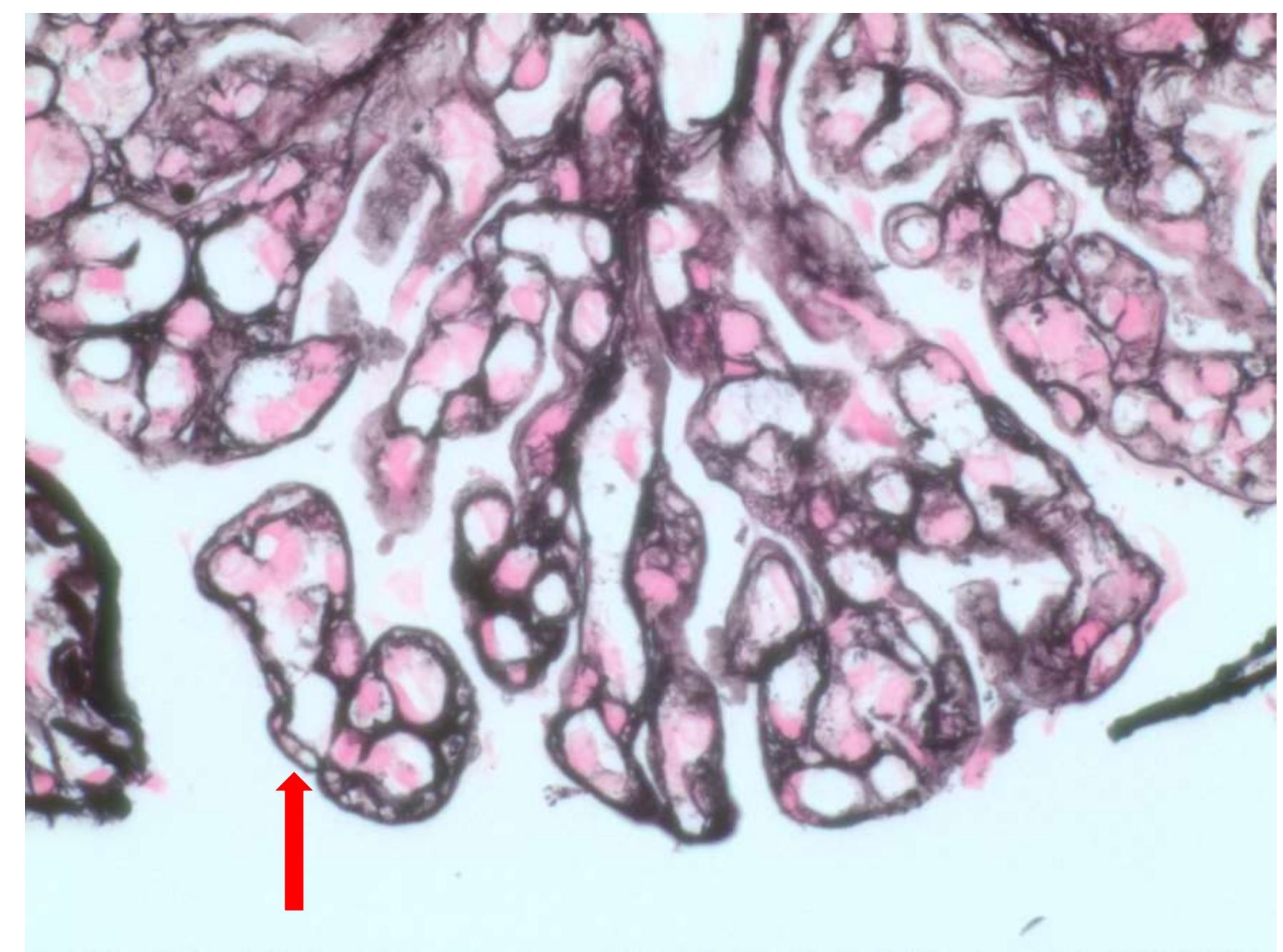
Electron Microscopy



Subendothelial humps usually seen in C3 Glomerulonephritis

EM required to differentiate between C3GN and DDD

Biopsy



C3 immunostaining with 2+ Florescence

IF required to diagnose C3 Glomerulopathy

Results

- Patient was noted to have double contoured BM, increased cellularity and mesangial expansion with capillary wall thickening on LM, Subendothelial humps on EM, and IF positive only for C3
- Noted to have C3 Glomerulonephritis

Conclusion

- Illustrates the necessity of a kidney biopsy to confirm the diagnosis of a suspected glomerulonephritis
- Overactive Complement System
 - 3 Pathways
 - Classical, Lectin, Alternative
 - All have different points of origin but converge at C3 to generate C3 Convertase Complex which cleaves C5 into C5a and C5b
 - Activates the Terminal Complement Cascade giving rise to MAC Complex and Cell Lysis
- Current treatments include supportive care with BP goal <120/80, RAAS Blockage with ACEI/ARB for all patients.
- Subset of patients with >500mg/24h urinary protein or progression of disease are treated with immunosuppression with MMF and steroids
- Investigational drug trials into Eculizumab have not shown success
- Despite current available treatments, progression to ESRD after 10 years following diagnosis is about 50%
- Investigations into KTx in ESRD secondary to C3GN had high likelihood of disease recurrence and possible graft loss
- Further investigations into therapeutics that can block C3 Convertase formation would potentially treat this disease process

References

1. Koopman, J. J. E., Teng, Y. K. O., Boon, C. J. F., van den Heuvel, L. P., Rabelink, T. J., van Kooten, C., & de Vries, A. P. J. (2019). Diagnosis and treatment of C3 glomerulopathy in a center of expertise. *Neth J Med*, 77(1), 10-18.
2. Le Quintrec, M., Lapeyraque, A. L., Lionet, A., Sellier-Leclerc, A. L., Delmas, Y., Baudouin, V., . . . Fakhouri, F. (2018). Patterns of Clinical Response to Eculizumab in Patients With C3 Glomerulopathy. *Am J Kidney Dis*, 72(1), 84-92. doi:10.1053/j.ajkd.2017.11.019
3. Le Quintrec, M., Lionet, A., Kandel, C., Bourdon, F., Gnemmi, V., Colombat, M., . . . Fakhouri, F. (2015). Eculizumab for treatment of rapidly progressive C3 glomerulopathy. *Am J Kidney Dis*, 65(3), 484-489. doi:10.1053/j.ajkd.2014.09.025
4. Medjeral-Thomas, N. R., O'Shaughnessy, M. M., O'Regan, J. A., Traynor, C., Flanagan, M., Wong, L., . . . Cook, H. T. (2014). C3 glomerulopathy: clinicopathologic features and predictors of outcome. *Clin J Am Soc Nephrol*, 9(1), 46-53. doi:10.2215/CJN.04700513
5. Pickering, M. C., D'Agati, V. D., Nester, C. M., Smith, R. J., Haas, M., Appel, G. B., . . . Cook, H. T. (2013). C3 glomerulopathy: consensus report. *Kidney Int*, 84(6), 1079-1089. doi:10.1038/ki.2013.377
6. Regunathan-Shenk, R., Avasare, R. S., Ahn, W., Canetta, P. A., Cohen, D. J., Appel, G. B., & Bomback, A. S. (2019). Kidney Transplantation in C3 Glomerulopathy: A Case Series. *Am J Kidney Dis*, 73(3), 316-323. doi:10.1053/j.ajkd.2018.09.002