

Henry Ford Health System

Henry Ford Health System Scholarly Commons

Case Reports

Medical Education Research Forum 2020

5-2020

A Case of Metastatic Squamous Cell Carcinoma in a Patient with Recessive Dystrophic Epidermolysis Bullosa that was Responsive to Pembrolizumab, a Programmed Cell Death Protein 1 Inhibitor

Danielle Yeager

Henry Ford Health System, dyeager2@hfhs.org

Molly Powers

Henry Ford health System, mpowers3@hfhs.org

David M. Ozog

Henry Ford Health System, dozog1@hfhs.org

Follow this and additional works at: <https://scholarlycommons.henryford.com/merf2020caserpt>

Recommended Citation

Yeager, Danielle; Powers, Molly; and Ozog, David M., "A Case of Metastatic Squamous Cell Carcinoma in a Patient with Recessive Dystrophic Epidermolysis Bullosa that was Responsive to Pembrolizumab, a Programmed Cell Death Protein 1 Inhibitor" (2020). *Case Reports*. 3.

<https://scholarlycommons.henryford.com/merf2020caserpt/3>

This Poster is brought to you for free and open access by the Medical Education Research Forum 2020 at Henry Ford Health System Scholarly Commons. It has been accepted for inclusion in Case Reports by an authorized administrator of Henry Ford Health System Scholarly Commons.

A Case of Metastatic Squamous Cell Carcinoma in a Patient with Recessive Dystrophic Epidermolysis Bullosa that was Responsive to Pembrolizumab, a Programmed Cell Death Protein 1 Inhibitor

Danielle Yeager, MD, Molly Powers, MD, and David M. Ozog, MD
Henry Ford Health System Department of Dermatology



Purpose

- Cutaneous squamous cell carcinomas (SCCs) are the leading cause of death in patients with recessive dystrophic epidermolysis bullosa (RDEB).
- Management of SCCs in these patients is challenging with higher rates of recurrence and lymph node metastases.
- Although surgery is the first-line treatment in the majority of cases, certain clinical situations, such as regional recurrence or distant metastasis, may call for nonsurgical treatment such as chemotherapy, immunotherapy, or radiation.
- We report the complex management of SCCs in a young female patient with RDEB whose nodal disease responded successfully to the programmed cell death protein 1 (PD-1) inhibitor, pembrolizumab.

Case

- Patient is a 29-year-old female with a long-standing history of RDEB complicated by multifocal and recurrent SCC of the skin.
- She initially presented in 2015, at the age of 24, for SCC of the skin that was treated with a combination of Mohs micrographic surgery (MMS), wide local excision, and laser-assisted topical delivery of aminolevulinic acid.
- Over the next 6 months, she continued to develop several additional invasive SCCs.
- Computed tomography (CT) scan revealed bilateral pulmonary nodules and axillary nodes concerning for early metastatic disease.
- Left axillary node biopsy performed was negative for metastatic disease, and these were thought to be consistent with a reactive process.

Therapy and Course

- Oncology recommended off-label palliative use of cetuximab given her multifocal disease and higher risk of metastasis in RDEB patients.
- She completed 4 cycles of cetuximab complicated by sepsis, likely from a cutaneous source, as well as a grade 2 EGFR-associated acneiform eruption.
- After 4 cycles, her CT remained stable, and there was no evidence of cutaneous recurrence
- The decision was made to discontinue cetuximab.
- However, 2 years following the cessation of cetuximab she developed multiple cutaneous recurrences and a surveillance CT scan showed enlargement of her left axillary lymph nodes to a mass of 3.7 x 4.0 cm in size.
- Nodal biopsy revealed metastatic SCC and molecular testing performed showed that 100% of tumor cells (tumor proportion score) were positive for PD-L1 staining.
- The decision was made to start pembrolizumab as off-label therapy with plans to pursue axillary node excision after she completed treatment.
- At the completion of these 4 cycles, a repeat CT scan showed improvement in the enlarged nodes with reduction to 2.2 x 1.4 cm in size.
- Regional lymph node resection was then successfully performed 4 months after her last infusion.
- Pathology of the excised lymph nodes revealed only keratinaceous material without definitive malignant cells indicative of her therapeutic response. (Figure 1)
- Long term longitudinal follow up is still required to determine durability of her clinical response.

Histopathology

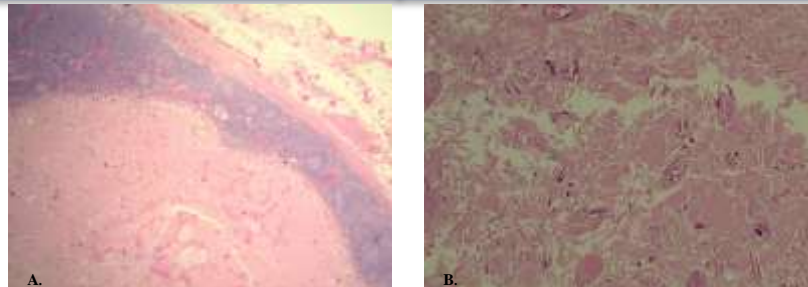


Figure 1: Left axillary node dissection showed 1 enlarged node with keratin debris with pearls but no definitive epithelial cells required for the definition of metastatic carcinoma

Summary

- Pembrolizumab was the first PD-1 inhibitor approved by the Food and Drug Administration (FDA) for metastatic melanoma.
- Recently in clinical trials, a new PD-1 inhibitor cemiplimab showed a 50% response rate (either partial or complete) in the treatment of cutaneous SCC and became the first systemic drug in its class to be approved for the treatment of locally advanced or metastatic cutaneous SCC.
- We report the first case of metastatic SCC in a RDEB patient that responded to treatment with the PD-1 inhibitor, pembrolizumab.

Conclusion

- Immunotherapy with PD-1 inhibitors, such as pembrolizumab, may be an additional treatment modality for SCC in RDEB patients with late stage or metastatic disease.
- Further larger scale studies are warranted to determine the utility of PD-1 inhibitors in the multimodal management of these high-risk patients.

References

1. Venugopal SS, Murrell DF. Treatment of skin cancers in epidermolysis bullosa. *Dermatol Clin*. 2010;28:283-287. Amin SM, et al. Combined cutaneous tumors with a melanoma component: A clinical, histologic, and molecular study. *J Am Acad Dermatol*. 2015;73(3):451-60.
2. Chang AL, Kim J, Luciano R, et al. A Case Report of Unresectable Cutaneous Squamous Cell Carcinoma Responsive to Pembrolizumab, a Programmed Cell Death Protein 1 Inhibitor. *JAMA Dermatol*. 2016;152:106-108.